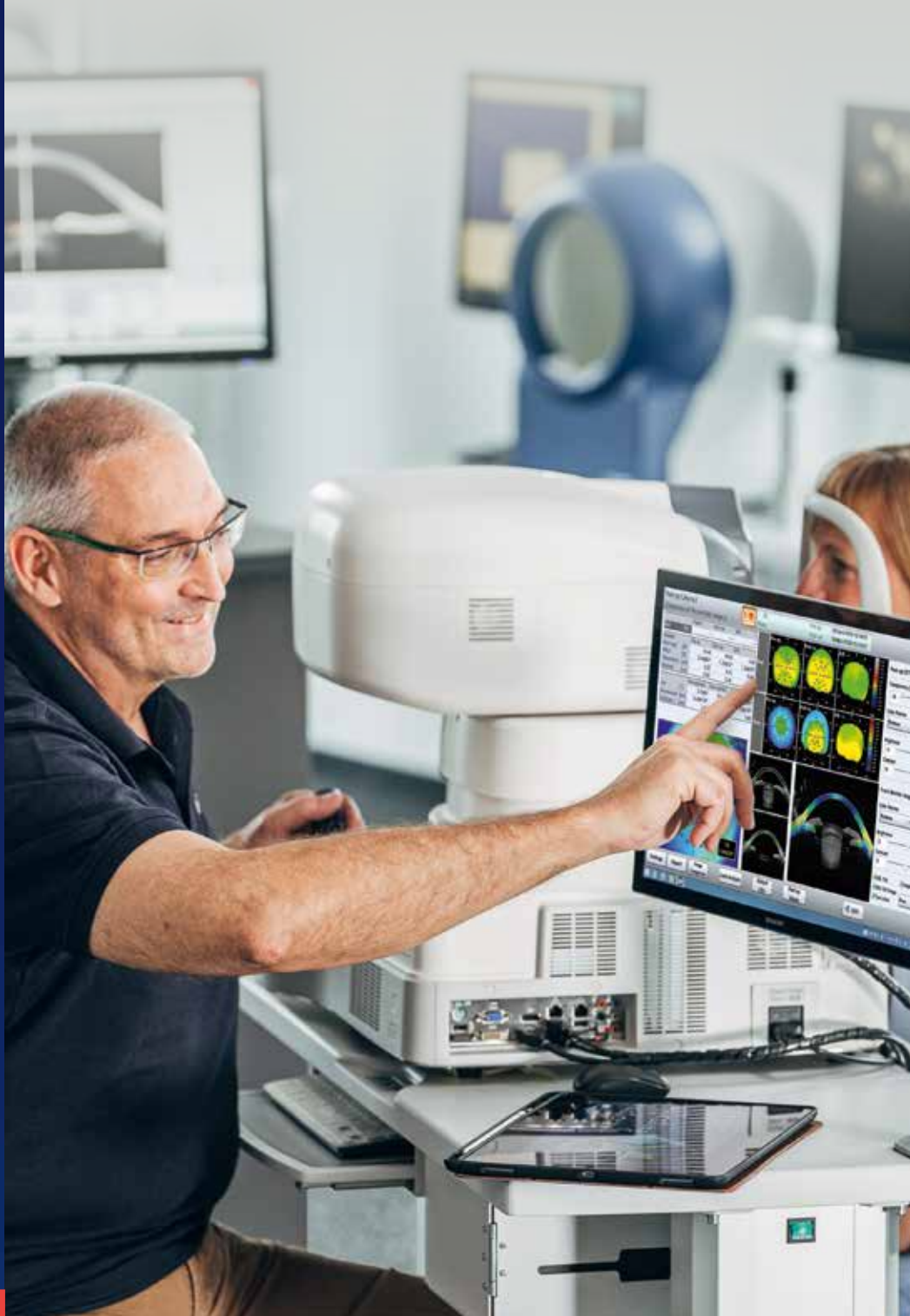



CASIA2

USER EXPERIENCE

CASIA2

Cornea/Anterior Segment OCT

Discover the power of CASIA2 through real-world cases provided by eye care professionals like you. In this brochure, we proudly present a collection of diverse patient experiences that showcase the versatility and clinical utility of CASIA2 Cornea / Anterior Segment OCT.

Dive into the insights, outcomes, and lessons learned from these cases, and see firsthand how CASIA2 is transforming ophthalmic care.

Optimise clinical decision-making with the CASIA2 technology

- + Testing application for cataract/glaucoma/cornea surgery
- + Special glaucoma analysis (STAR 360°)
- + Advanced imaging with deep scanning depth (13 mm)
- + Very fast scanning speed (50,000 A-scans/second)
- + Corneal topography, trend analysis, IOL choice, and calculation
- + Lens shape analysis incl. tilt and decentration
- + Phakic IOL simulation
- + ICL Pre- and Post-OP application
- + Colour fixation camera

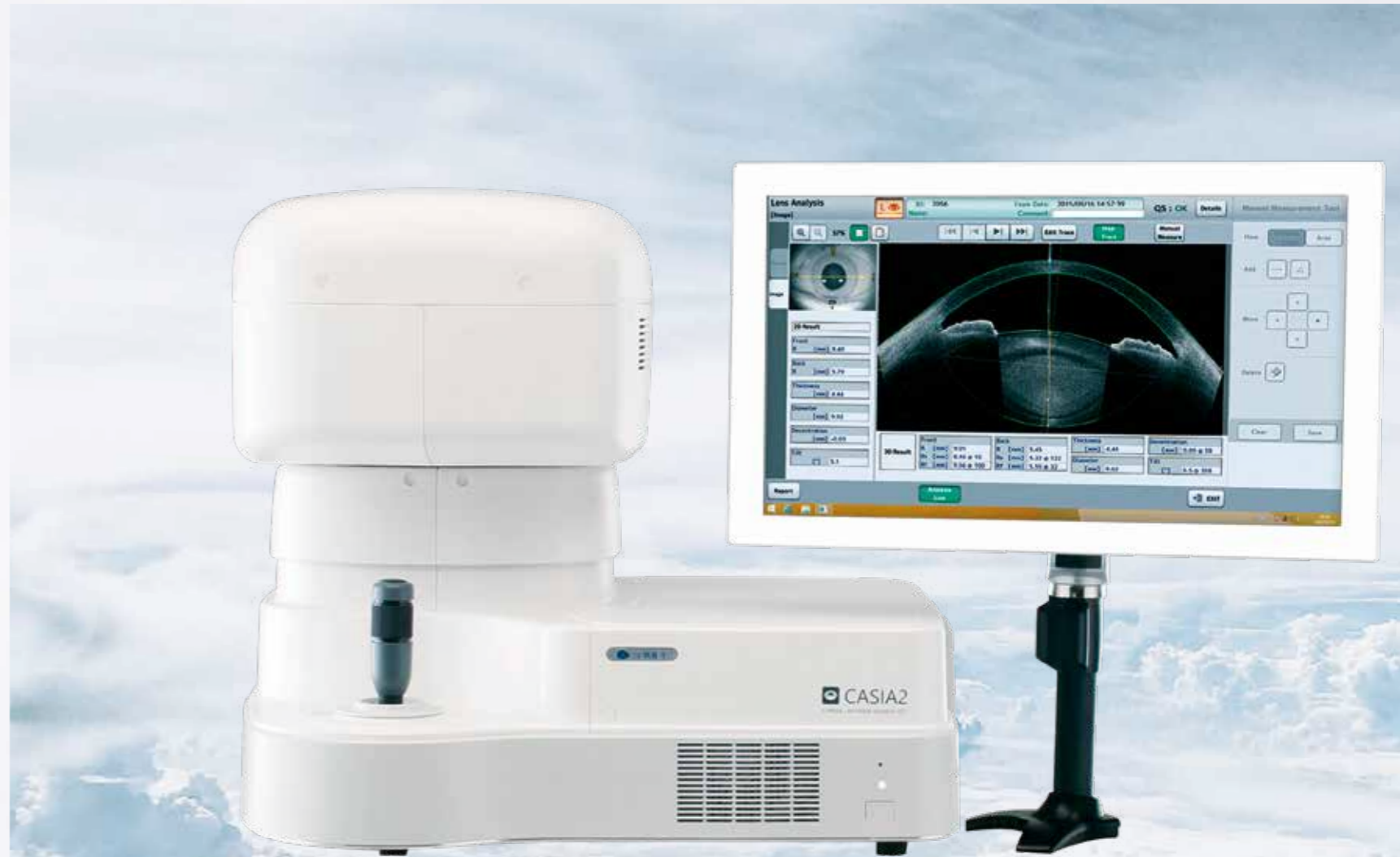

Table of contents

CONTENT FROM CASIA2 USERS

Felix Gonzalez-Lopez MD, PhD	p. 4
Prof. Dr. Timo Eppig/Dr. Eckhard Becker / Violetta Müller	p. 8
Dr. Carlos Gutiérrez	p. 10
Dr. Merieme Harouch	p. 12
Priv. Doz. Dr. Nino Hirsenschall, PhD, FEBO, MhBA/Christopher Reischl BSc.	p. 14
William Kay/Ayan Abdullahi/Madyan Qureshi	p. 16
Ignacio Rodriguez-Una MD, PhD	p. 18
Dr. Pau Romera	p. 22
Dr. Stephan Szegedi	p. 26
Ana Trpeska Boshkoska MD	p. 30
Dr. Jorge Vila Arteaga	p. 32

CONTENT FROM TOMEY

Glaucoma application	p. 21
ICL surgery	p. 25
Join this project	p. 29
apEye	p. 34



Felix Gonzalez-Lopez MD, PhD
 Medical Director,
 Clinica MIRANZA, Madrid (Spain)

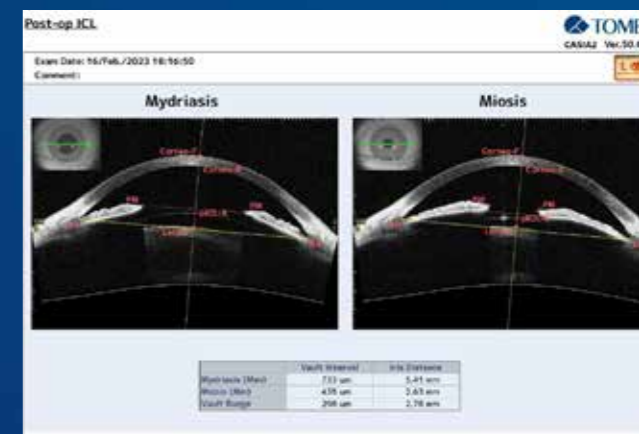
Introduction

1. Anterior Segment Optical Coherence Tomography (AS-OCT) represents an unparalleled tool for assessing the anterior pole of the eye, providing a novel approach to studying the anterior segment. This innovation has led to a significant paradigm shift in preoperative calculations for sizing posterior chamber phakic lenses.

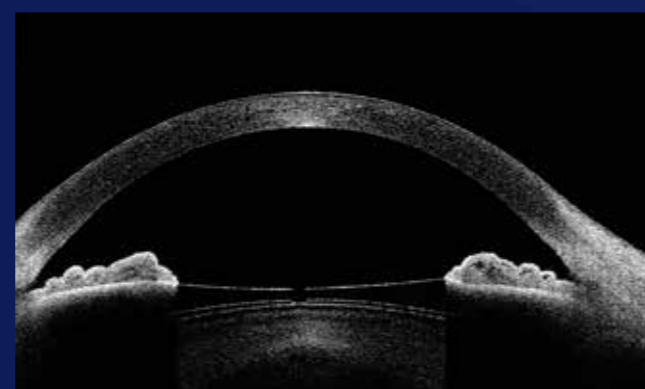
One of the latest enhancements to the CASIA2 is the **Post-op ICL** application that facilitates quick and straightforward postoperative assessment of posterior chamber phakic lenses. I have had the privilege of actively contributing to its development. With this application, we can now not only visualise but also measure the dynamic vault of the ICL, observing how it varies with external lighting conditions. Moreover, it enables graphical assessment of the relationship between pupil size, the optic zone of the phakic lens, and the status of the iridocorneal angle. The imagery it provides under scotopic and photopic conditions, easily exportable to medical records, fulfills the criteria every clinician seeks when examining an eye implanted with an ICL.

With the introduction of this new application, the **CASIA2** unquestionably emerges as the most potent imaging device available for postoperative evaluation of ICLs.

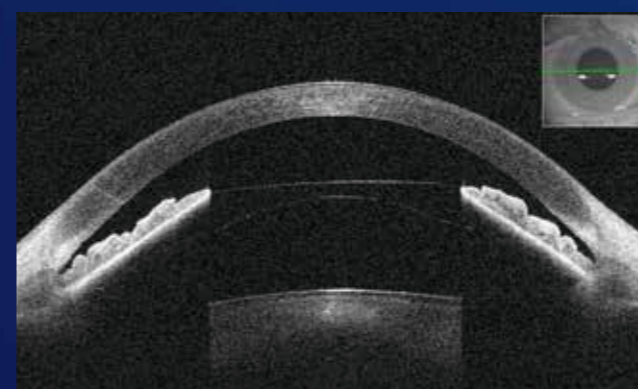
2. In 2018, we introduced what we termed the **dynamic concepts of vault** (Gonzalez-Lopez F, et al. Dynamic assessment of light-induced vaulting changes of implantable collamer lens with central port by swept-source OCT: Pilot study. Trans Vis Sci Tech. 2018;7(3):4. <https://doi.org/10.1167/tvst.7.3.4>). In this paper, we outlined the novel parameters **vault interval (VI)**, which we defined based on central vault values during maximum mydriasis and maximum miosis following light-induced changes in pupil diameter, and **vault range (VR)**, calculated as the absolute difference between the VI values. In our initial pilot study, we found that the mean VR was $167 \pm 70 \mu\text{m}$. Through a collaborative effort with TOMEY, we were able to integrate the dynamic vault concept into an application, the **Post-op ICL**, now accessible in CASIA2.



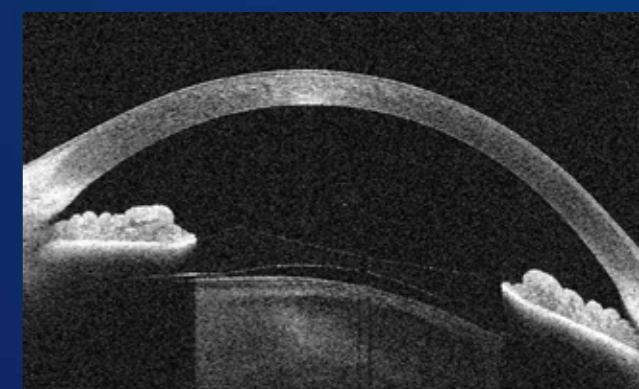3. The dynamic images captured by the **video application**, recorded under controlled scotopic and photopic ambient lighting conditions, offer us an authentic perspective on the interactions between the ICL and different structures of the anterior ocular segment. Combined with the **Post-op ICL** application's ability to quantify these changes, this leads us to introduce another new concept: the **relativism of the vault**. Consequently, it enables us to determine, on a case-by-case basis, whether pupillary dynamics, iridocorneal angles, and vault are optimal, or conversely, whether explantation and replacement with an ICL of a different size is necessary.



Low central vault

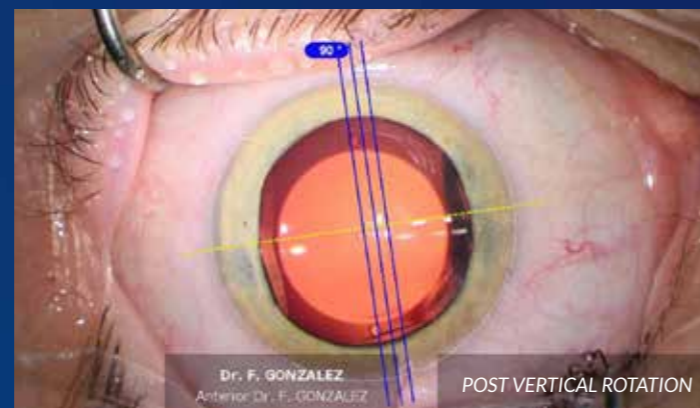
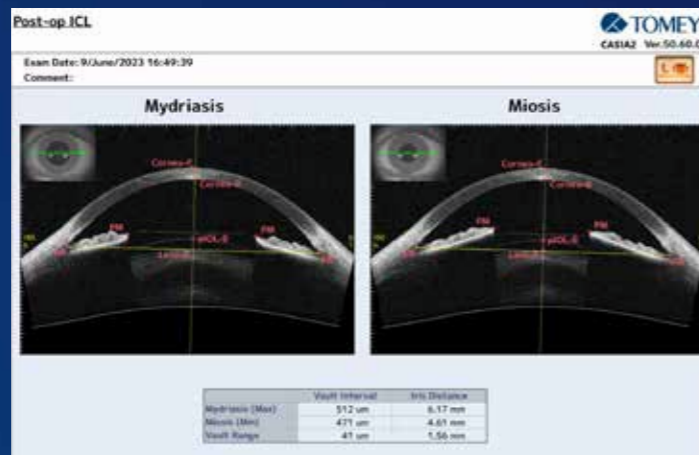
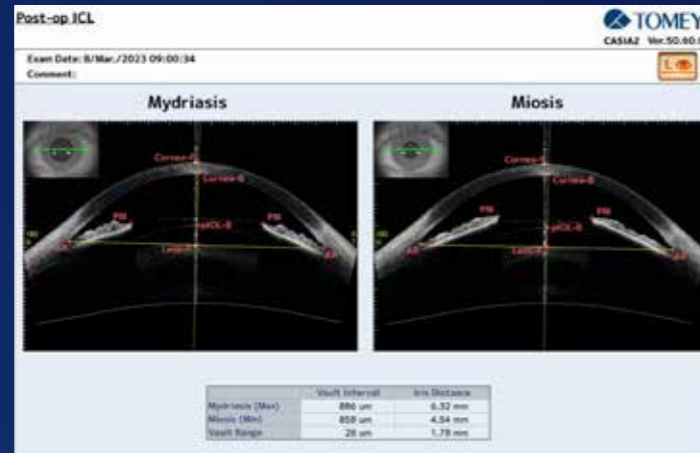

High vault

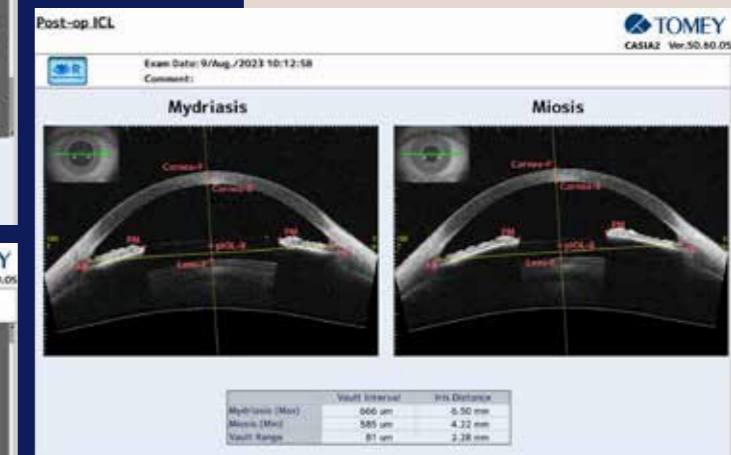
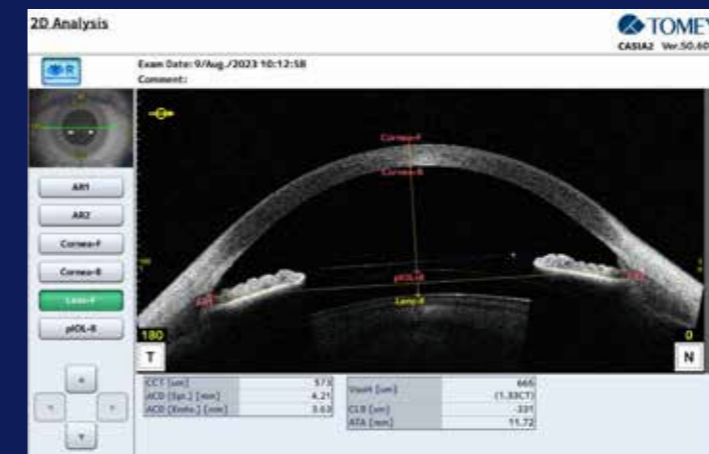
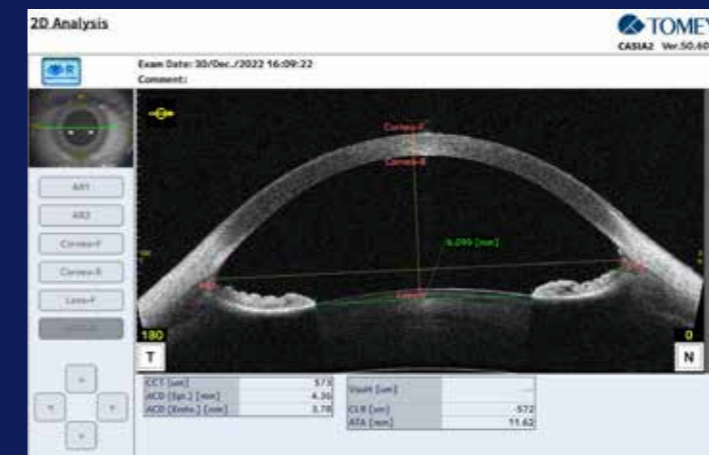


Low peripheral vault

Alternatively, as demonstrated in the example presented, rotating the phakic lens vertically can reduce vault and thereby improve pupillary dynamics. This surgical maneuver successfully alleviated the dysphotopsias experienced by the patient in this case.



4. Preoperative evaluation of **iris morphology**, its displacement under varying external lighting conditions, and **crystalline lens rise (CLR)** undoubtedly aids in selecting the appropriate ICL size. In this instance, a notably low CLR, coupled with a deep anterior chamber depth (ACD) and concave iris shape, will impact the choice of ICL size. It is noteworthy to observe the enhancement in pupillary dynamics and the modification in the relationship between the iris and the crystalline lens following ICL implantation.



Case 1

CASIA2 for Measuring the Ciliary Sulcus in Order to Determine the Size of an Accommodating Intraocular Lens

Introduction

The Lumina accommodating intraocular lens is a dual-optic lens system intended for implantation in the ciliary sulcus. The mechanism of action is based on the Alvarez lens principle. The lens is directly driven by the ciliary muscle, which laterally displaces the two lens components. The performance of the Lumina is directly depending on a perfect fit in the ciliary sulcus and they are therefore custom-made for each eye. Therefore, precise measurement of the sulcus dimensions is crucial for the procedure's success.

Ultrasound imaging provides poor resolution, even with high-frequency probes, so instead we use the CASIA2 for precise direct measurement of the ciliary sulcus. This is not only more comfortable for the patient but also delivers superior image quality.

Methods

We created a set of Scan Types using up to 64 averaging frames to reduce image noise. This improved the image quality in the ciliary sulcus so that the measurement tool in the 2D Analysis mode can be used to directly measure the width of the ciliary sulcus (Figure 1). It was measured in three different meridians.



Prof. Dr. Timo Eppig

Adjunct professor of Experimental Ophthalmology at Saarland University, Homburg (Germany), Senior Consultant and Head of Research and Development at AMPLANT GmbH, Schnaittach (Germany)

Dr. Eckhard Becker

Senior ophthalmic surgeon and co-owner at Augentagesklinik Oranienburg MVZ GmbH, Oranienburg (Germany) – a private eye clinic with several subsidiaries nearby Berlin (Germany)

Violetta Müller

Resident at Augentagesklinik Oranienburg MVZ GmbH, Oranienburg (Germany)

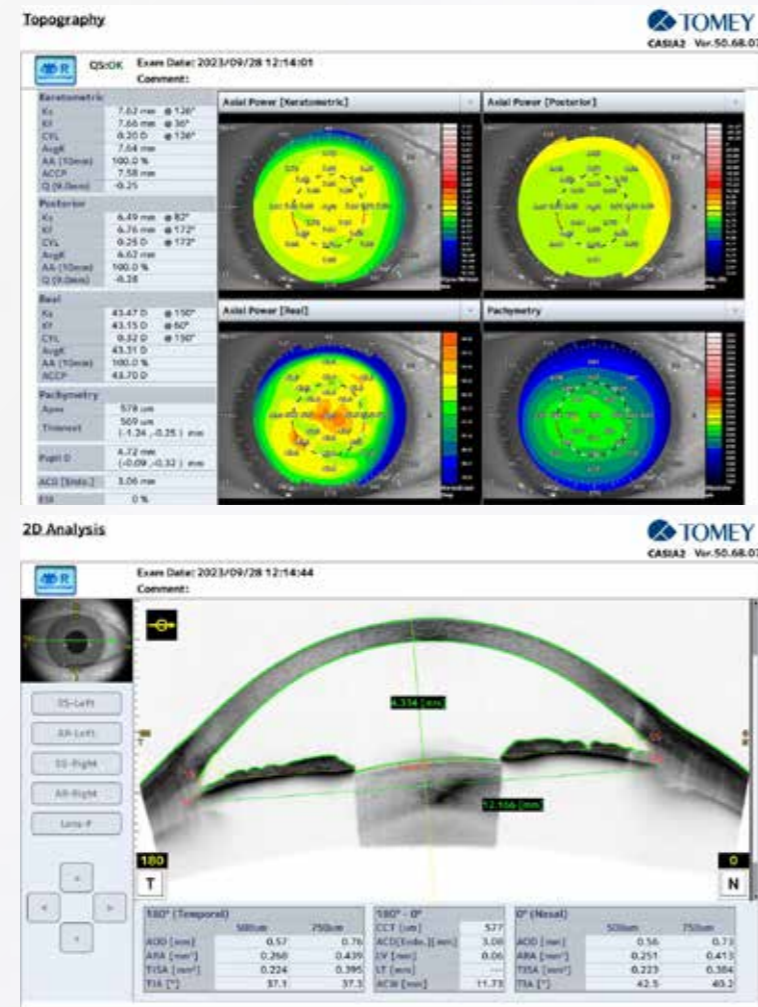


Figure 1: Preoperative measurement of the width of the ciliary sulcus and the distance of the sulcus plane to the corneal vertex

The Lumina is then manufactured using these measurements, and the accurate fit of the lens was assessed postoperatively using the same method; it showed a perfectly placed lens in the ciliary sulcus (Figure 2). The performance of the Lumina was then evaluated by the PowerRef3 (PlusOptix GmbH, Nürnberg). It exhibited an accommodative amplitude of up to 2.5 D with a stimulus of 3 D.

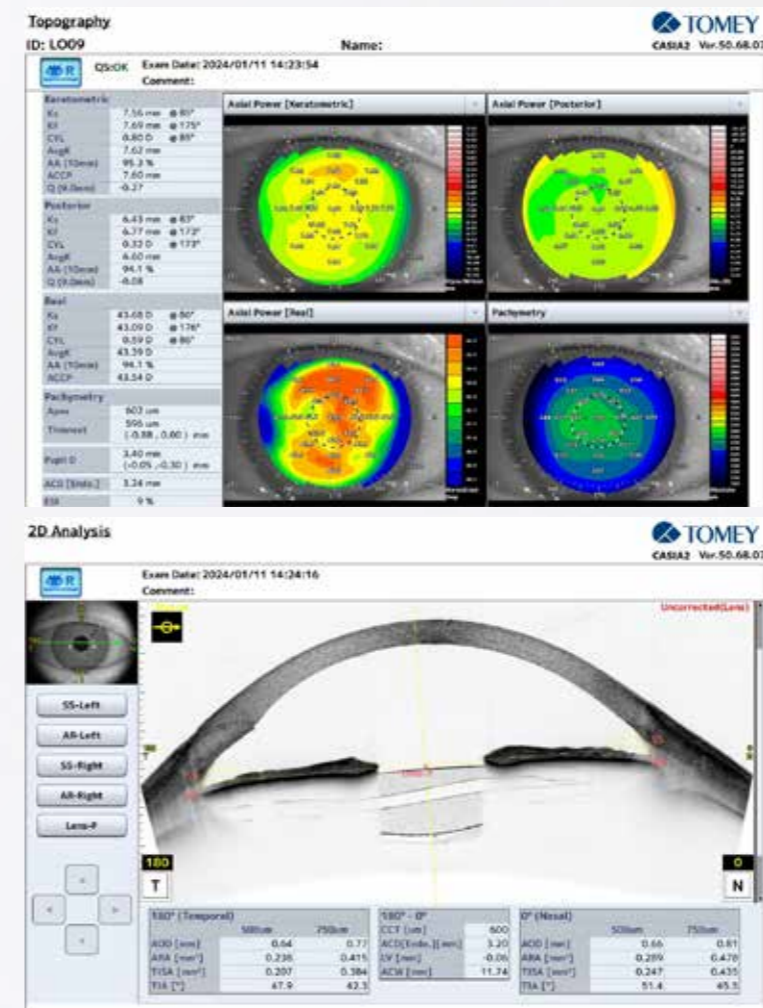
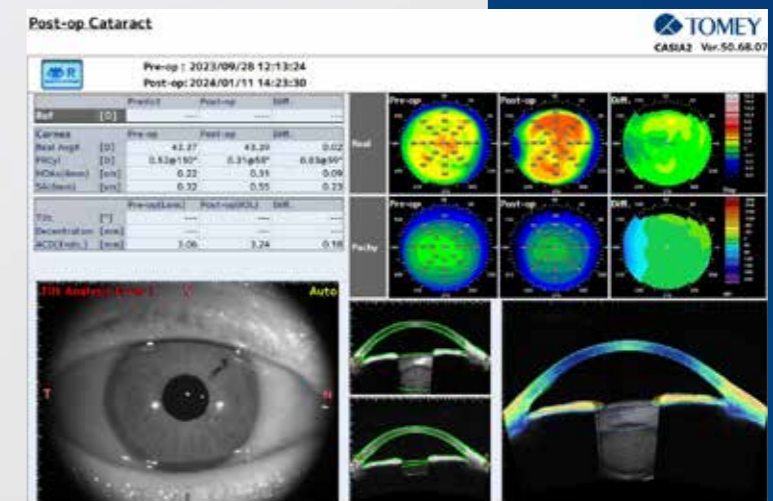

Figure 2: Postoperative image of the Lumina in the eye

Conclusion

The CASIA2 is the ideal instrument for pre- and postoperative assessment of the ciliary sulcus: It provides superior image quality compared to ultrasound imaging and is also faster and less burdensome to the patients.





Dr. Carlos Gutiérrez
 Medical Director,
 Clínica Vista Gutiérrez Amorós,
 A Coruña (Spain)

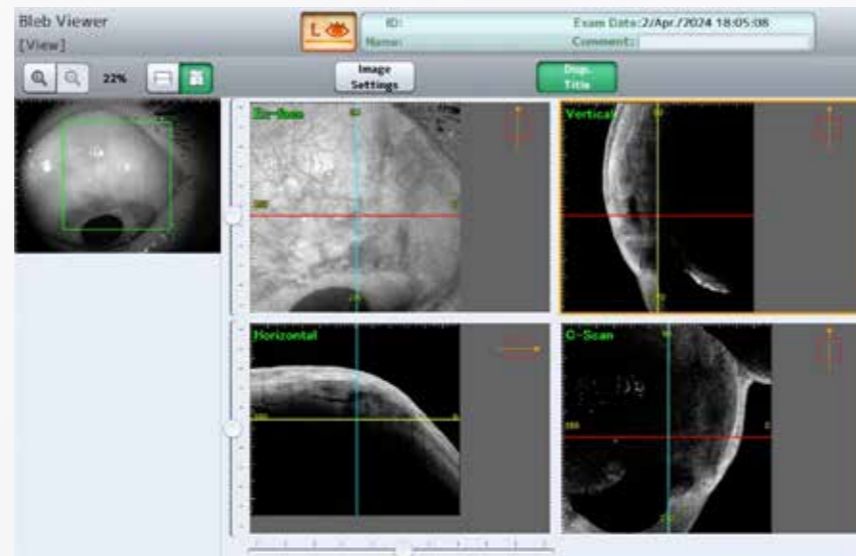The use of anterior chamber OCT has increased its potential over the years, providing more and higher-quality information. The CASIA2 has allowed us to offer a greater guarantee in the results of glaucoma surgeries by observing the effectiveness of these procedures instantly.

Case 1

Assessing ESNOPER V2000 Implant Permeability

Glaucoma implants serve to drain the aqueous humor in order to reduce intraocular pressure. For this reason, it is important to verify that these implants are permeable and effective.

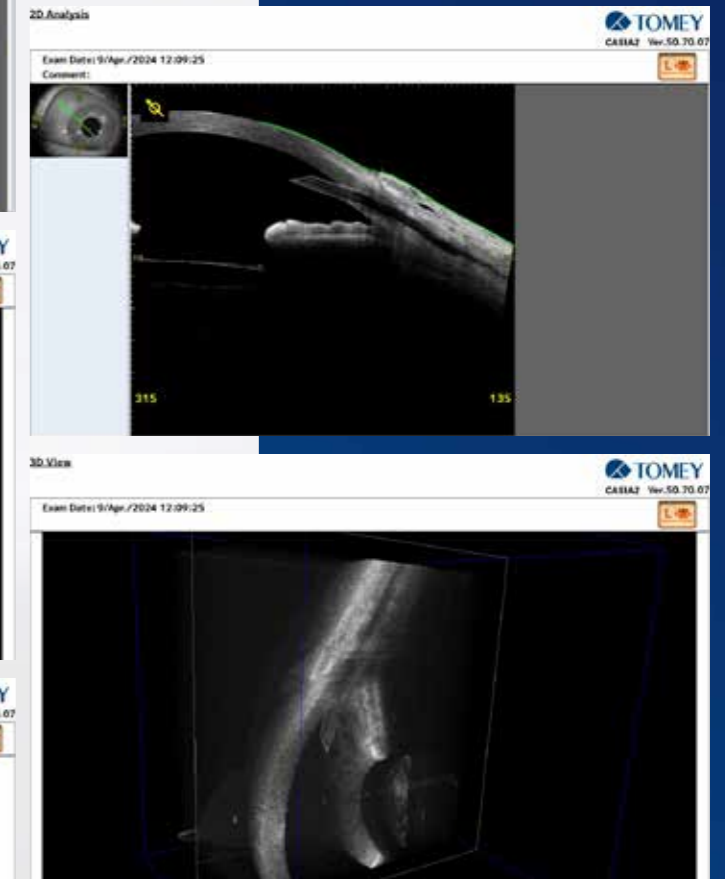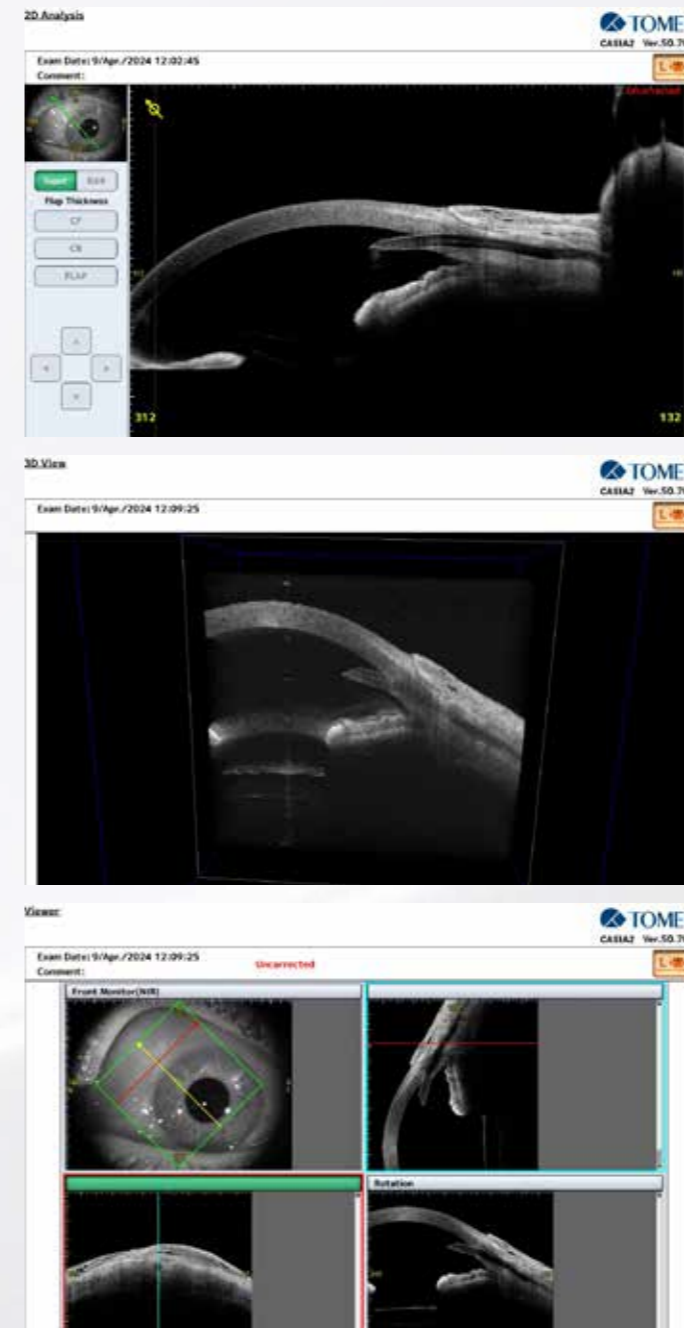As seen in the images, CASIA2 system allows us to precisely evaluate the permeability of the ESNOPER V2000 scleral implant. Using the “bleb” measurement system the valve’s permeability in all the sectors can be evaluated, and the intrascleral space can be analysed to determine if it is large enough.



Case 2

Evaluating Preserflo® Implant Efficiency

In devices used for the treatment of glaucoma, such as the Preserflo® implant, it is important to verify its position, depth, and effectiveness in reducing intraocular pressure through filtration. The use of the CASIA2 allows us to evaluate these parameters with a single measurement and a single image. With this, we can verify from the end of the implant in the anterior chamber to its functioning at the scleral level and the filtration capacity that is being produced. This undoubtedly provides a greater guarantee in the results of the surgery in the immediate postoperative period and in the control of the pathology in the long term.



Case 1

The First Asymmetric Ring AS6-300/150° Implantation in Keratoconus

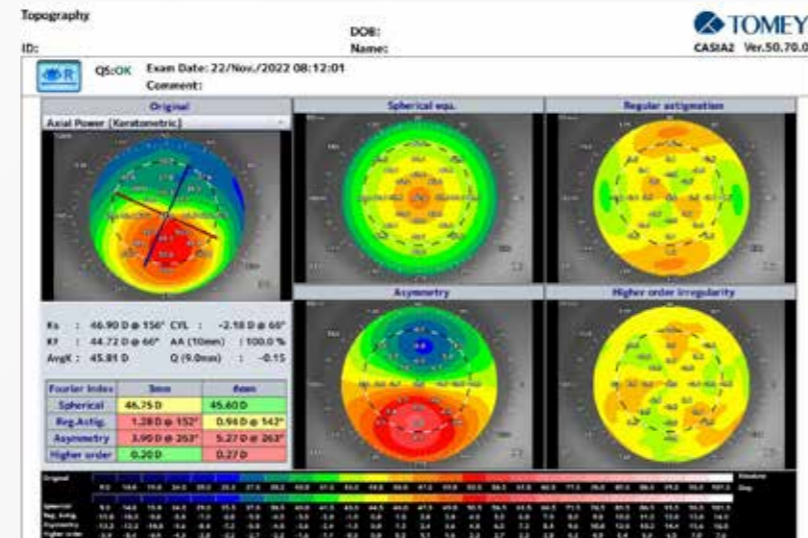
Refraction topo (axial power map) BCVA: 5/10 with (-3.50; 65)

Refraction on TOPO (Fourier Index asymmetry)

Refrac: BCVA (-3.50 [A]85°) = 1 elt of 8/10



Pr. As. Merieme Harouch
Cornea and refractive surgeon,
Casablanca cornée kératocône CCK,
Casablanca Laser Vision CLV,
Casablanca (Morocco)



Asymmetric corneal ring segment

Apical diameter: 6,80 mm

Base width: 800µ

Arc length: 150°

Thickness: 250-350-250

Tunnel parameters

Interior diameter: 5,95 mm

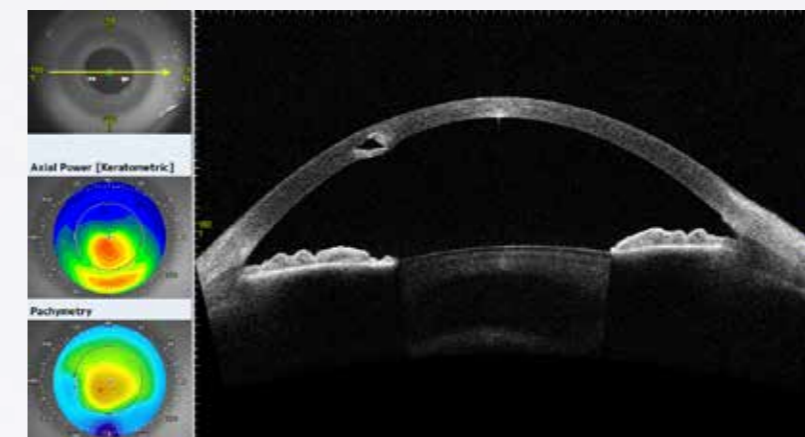
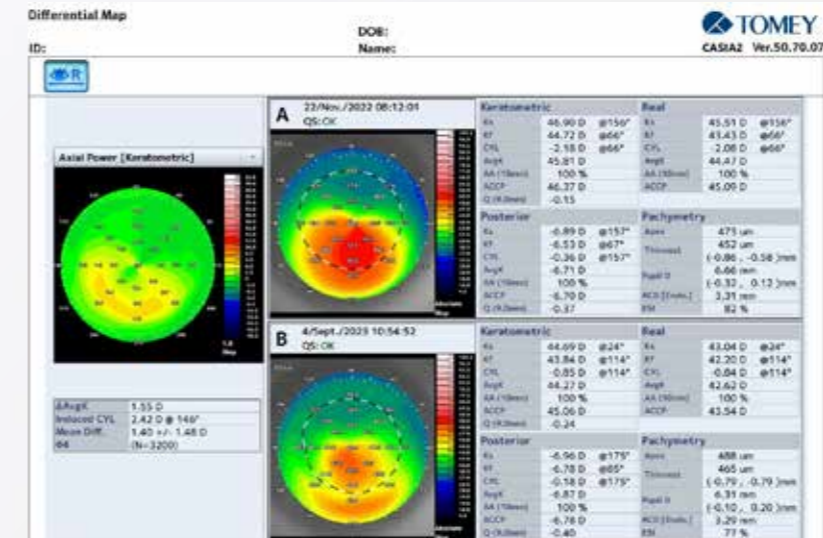
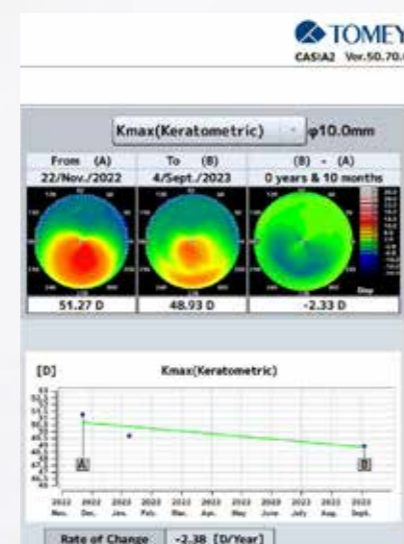
Exterior diameter: 7,35 mm

Interior depth = exterior depth:

80% thickness at implantation site

Comparative table of VA and Kmax

	UCVA	BCVA	Kmax
Before ICR	4/10	(-3.50 [A]85°) 1 elt of 7/10	51.30
After ICR	3 elts of 7/10	(-1.00 [A]115°) 2 elts of 8/10	48.93

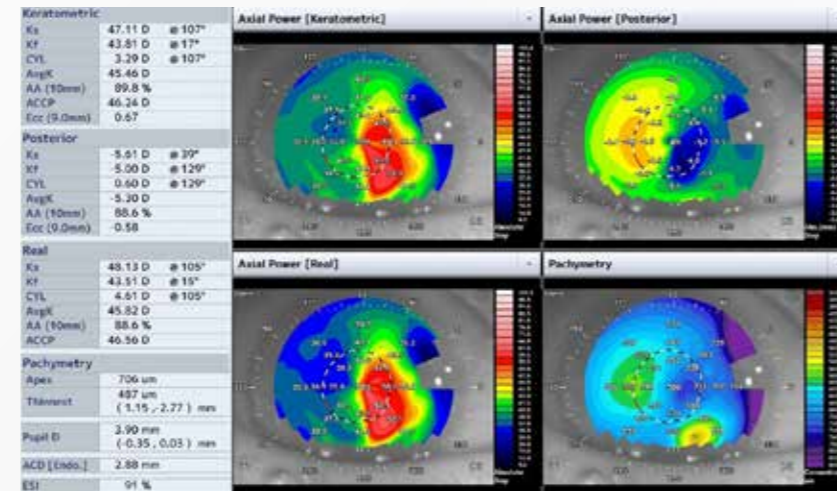


My conclusions

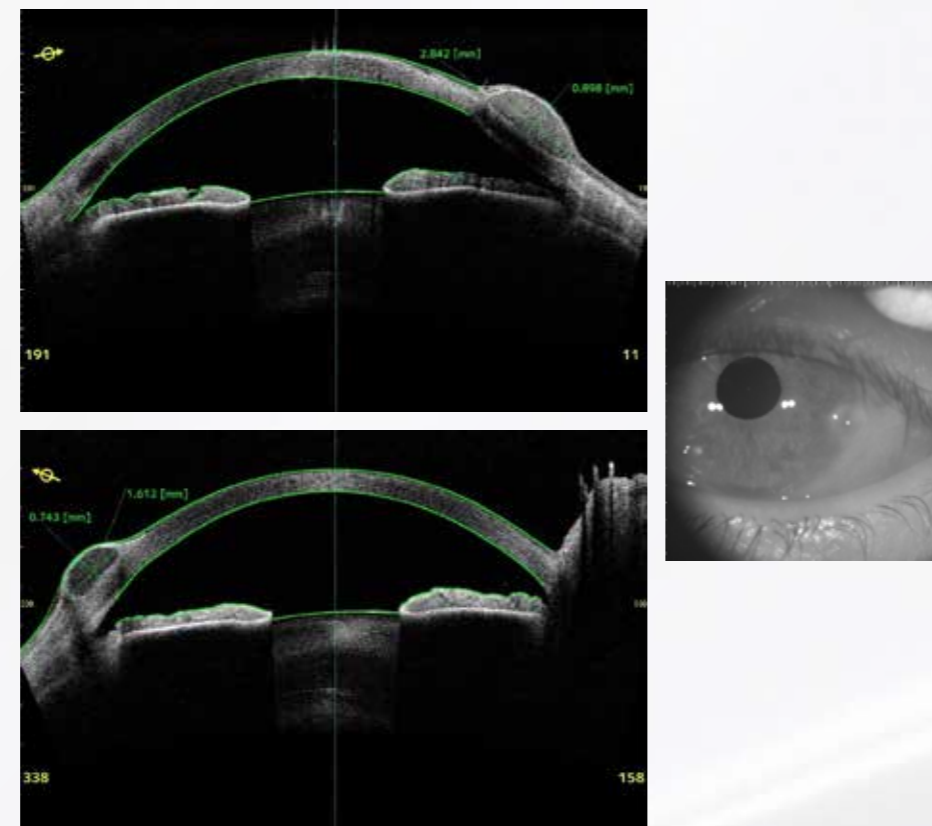
- + The Asymmetric ring AS6-150° 250/350/250 is effective in flattening the cornea.
- + The flattening is more important at the top of the ectasia where the ring is thickest (350).
- + The flattening gradually decreases at the periphery of the ectasia, where the two ends of the ring are thin (250µ).
- + The centering of the asymmetric ring on the axis of the Fourier axial asymmetry gave a good functional and topographic results.

Effectiveness on axial asymmetry and therefore on aberrations (Coma), in addition to effectiveness on the SE.

Case 1
Cyst at the Limbus

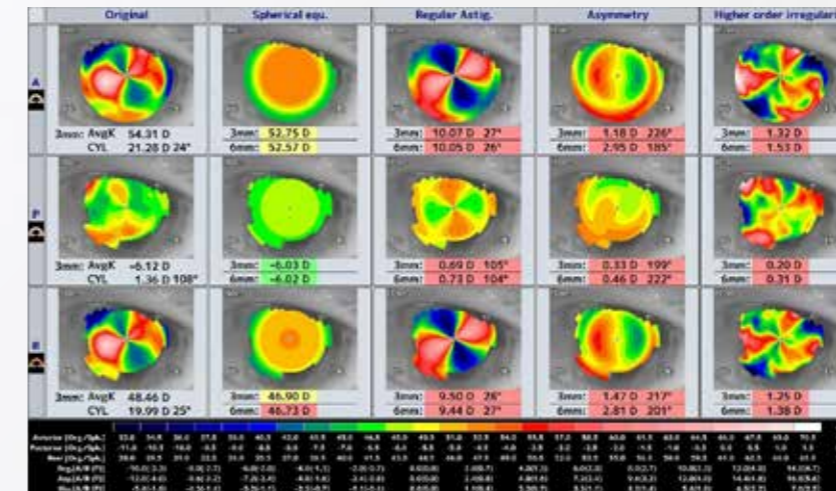


In this case of stem cell deficiency, cysts occurred on both eyes at the area of the limbus.

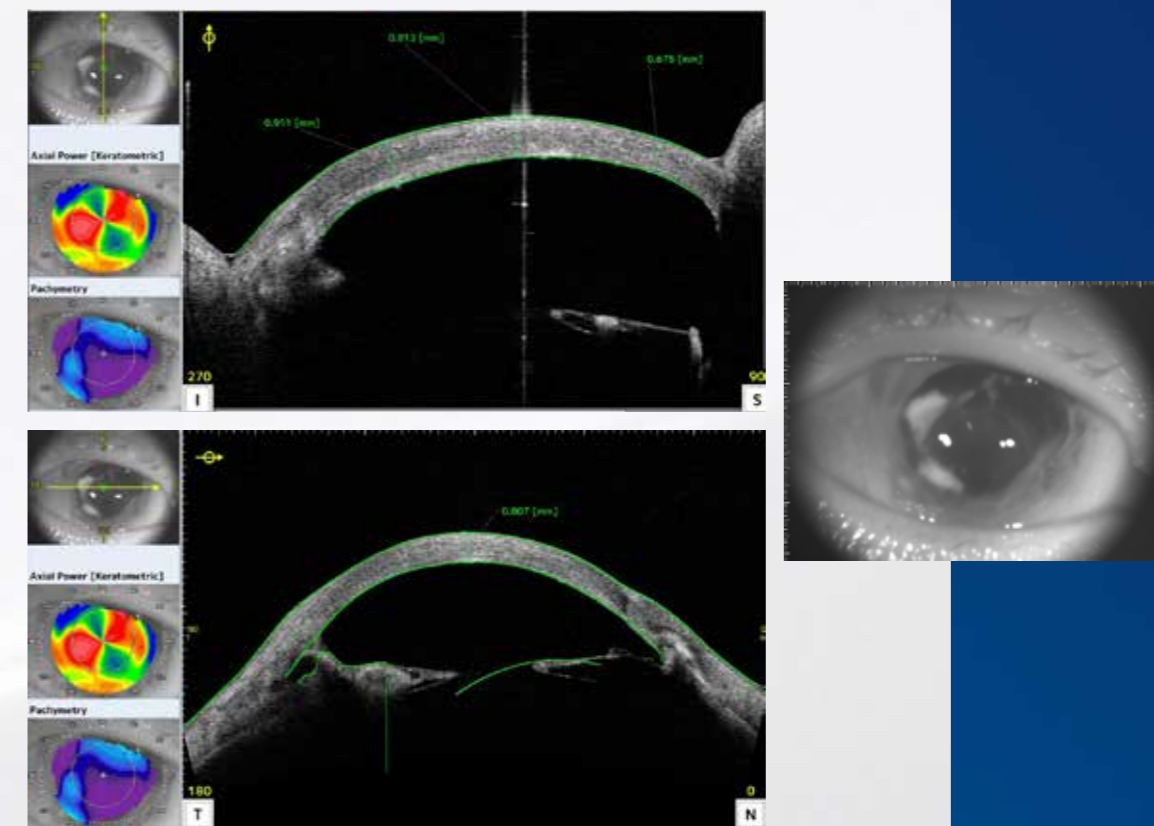


With the CASIA2 it was possible to observe corneal changes and measure the size and shape of the cysts from different angles. This resulted in a clearly visualised picture of the size of the cysts and enhanced the depth of information. Therefore, it was possible to evaluate the size and the lack of infiltration into the surrounding tissue, and then get a better understanding of the content of the cyst.

Case 2
Repeatedly Operated Eye



In this case, multiple surgeries were performed in the past including a traumatic cataract surgery without lens implantation in the 1950s, an anterior chamber IOL + removal, and several perforating keratoplasties due to severe herpetic infections.



With the CASIA2 it was possible to visualise the opacities in the pupillary plane. Therefore, it was possible to evaluate the extension and the area of these opacifications. Furthermore, the corneal imaging modalities permitted the evaluation of the regular and the irregular degree of astigmatism. With this information, it was much easier to decide which IOL should be used.



Priv. Doz. Dr. Nino Hirschall, PhD FEBO, MhBA
Department of Ophthalmology,
Kepler University Clinic, Linz (Austria)



Christopher Reischl BSc.
Department of Ophthalmology,
Kepler University Clinic, Linz (Austria)



William Kay
Lead Ophthalmic Science Practitioner,
Ophthalmic Imaging Department,
Royal Hallamshire Hospital,
Sheffield (United Kingdom)



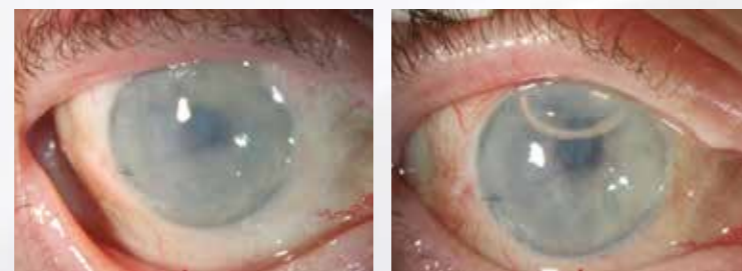
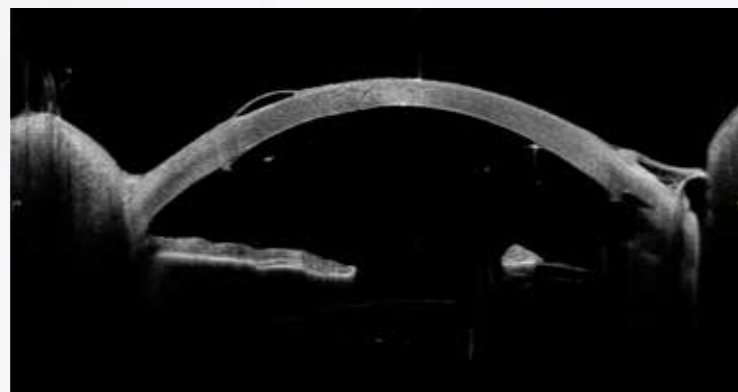
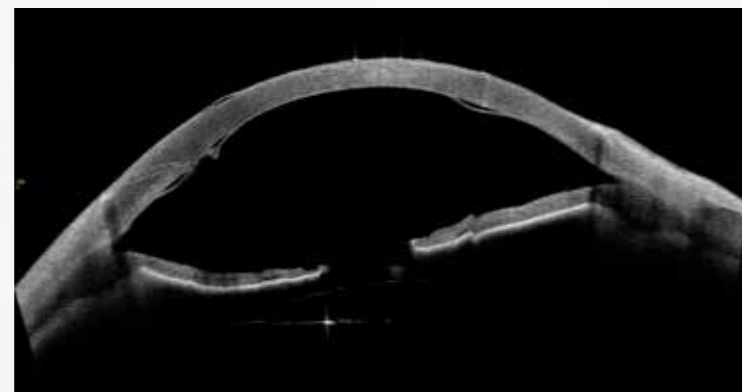
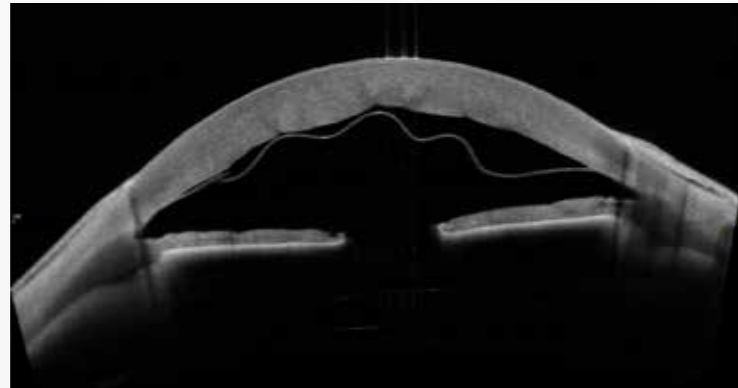
Ayan Abdullahi
Ophthalmic Science Practitioner

Madyan Qureshi
VR Clinical Fellow,
Sheffield Teaching Hospitals

Case 1

Descemet's Membrane Detachment (Pre-Op and Post-Op)

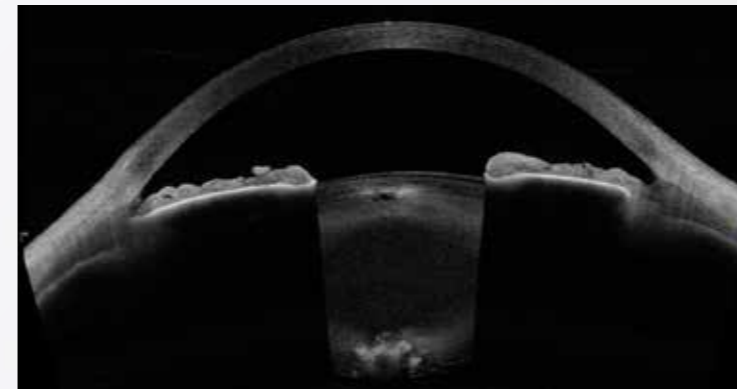
Patient had complicated cataract surgery with a small Descemet's membrane scroll intraoperatively. The patient was seen two days postoperatively and the cornea was very hazy, making it difficult to assess. The CASIA2 OCT demonstrated a clear Descemet's membrane detachment. The patient was brought back to theatre the same day and had an air tamponade injected to re-attach the Descemet's membrane. They were followed up with subsequent CASIA2 OCT scans to demonstrate successful re-attachment.



Case 2

Posterior Polar Cataract – Capsular Involvement

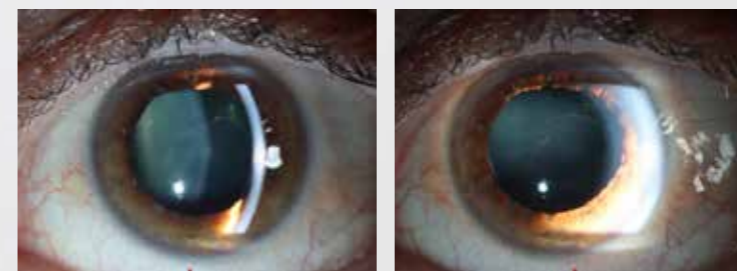
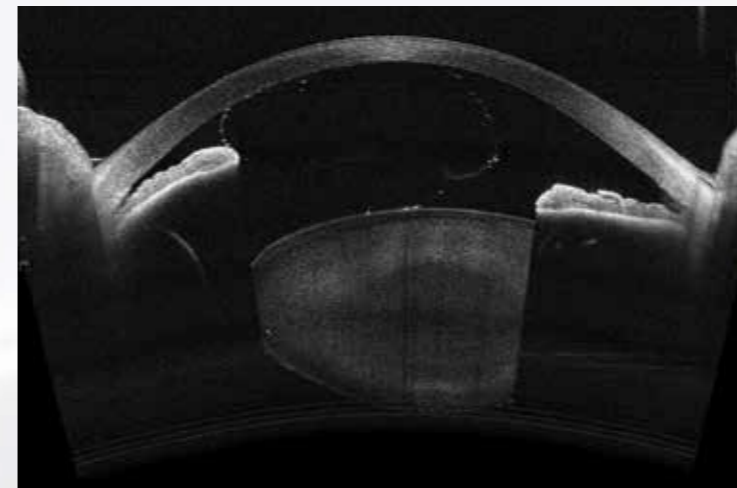
Patient was assessed in the cataract preoperative clinic with bilateral posterior polar cataracts. CASIA2 OCT was performed to assess the integrity of the posterior capsule. The scan revealed significant capsular involvement. This information allowed better surgical planning, and the patient had uncomplicated cataract surgery on a VR list.



Case 3

Subluxed Lens and Vitreous Prolapse Following Trauma

The patient had blunt force trauma resulting in traumatic mydriasis, zonular trauma, subluxed lens, and vitreous prolapse into the anterior chamber. The CASIA2 OCT demonstrated the relative position of the lens, iris, and vitreous prolapse.



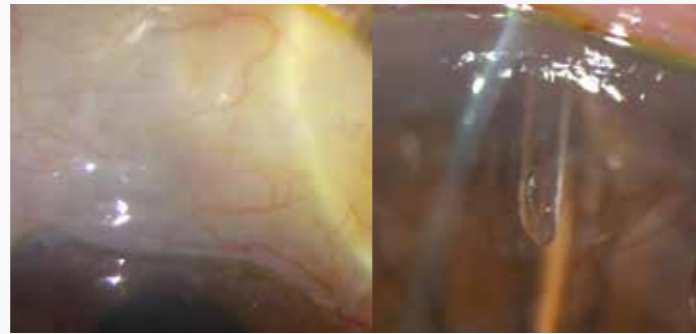


Ignacio Rodriguez-Una MD, PhD
 Fernandez-Vega Ophthalmological Institute, Ophthalmological Research Foundation (Fundacion de Investigacion Oftalmologica), University of Oviedo, Oviedo (Spain)

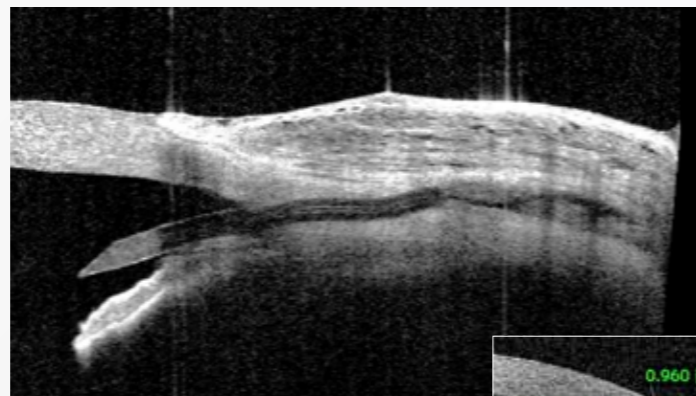
Anterior Segment Optical Coherence Tomography has been demonstrated to be a useful tool in the postoperative assessment of multiple glaucoma surgeries. This may be particularly relevant in bleb-forming techniques and in those procedures dependent of implants or other devices. In this user experience, several cases of different glaucoma surgeries are presented showing the improved imaging performance of CASIA2 and its utility.

Case 1

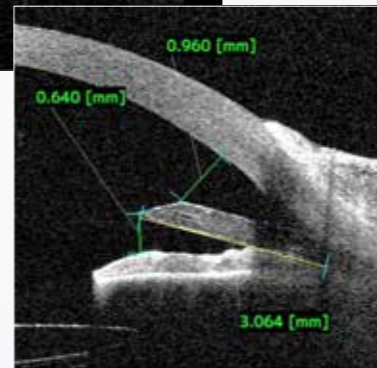
Preserflo® Microshunt* Glaucoma Surgery (Post-op 4 weeks)



Anterior segment images



CASIA2 cross-sectional image using "bleb" mode



CASIA2 anterior chamber cross-sectional image

With CASIA2 it is possible to identify the presence of fluid spreading out through the tissues, leading to multilayered conjunctiva. This sign has been reported to be a surgical success factor when it is detected in the early postoperative period.

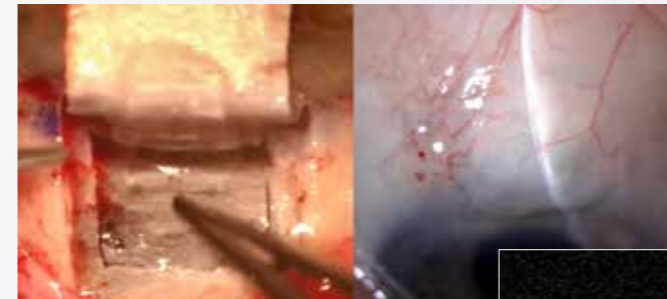
In terms of safety, one of the key points of this device is its relation with the anterior chamber structures after implantation, in particular with the corneal endothelium. CASIA2's calipre tool can be used to measure the distance from the tube to the endothelium and to the iris, as well as the total length of the tube inside the anterior chamber (from its exit throughout the irido-corneal angle).

*Santen Pharmaceutical Co., Osaka, Japan

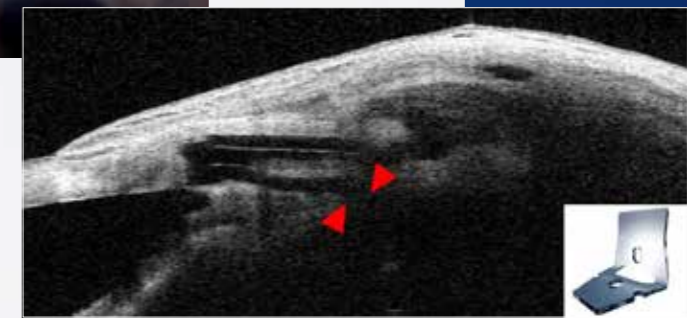
Case 2 A

Non-penetrating Deep Sclerectomy (NPDS) (Post-op 3 months)

Several non-absorbable implants for NPDS have been described. Due to the high-quality imaging performance and resolution of CASIA2, it is possible to clearly identify both plates of the ESNOPER CLIP® implant: the upper plate positioned on the scleral bed and the notched plate inserted in the supra-choroidal space (red arrow heads).



Intraoperative and anterior segment images

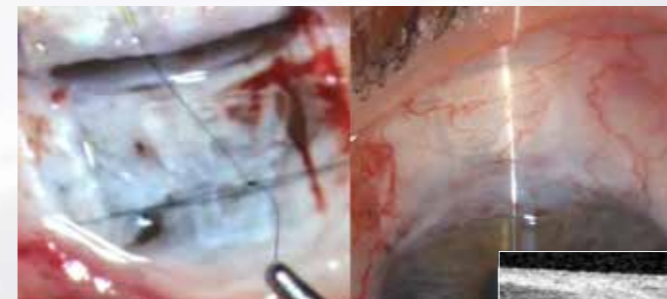

CASIA2 cross-sectional image using "bleb" mode

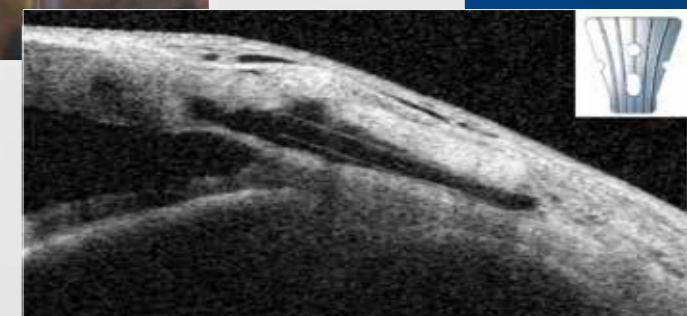Case 2 B

Non-penetrating Deep Sclerectomy (Post-op 1 week)

Differently, the ESNOPER V2000® is a single-plate design scleral implant that can be sutured with 10-0 nylon above the scleral bed. CASIA2 provides accurate information about the scleral lake and the drainage of aqueous humor.



Intraoperative and anterior segment images



CASIA2 cross-sectional image using "bleb" mode

*AJL ophthalmic, Vitoria, Spain

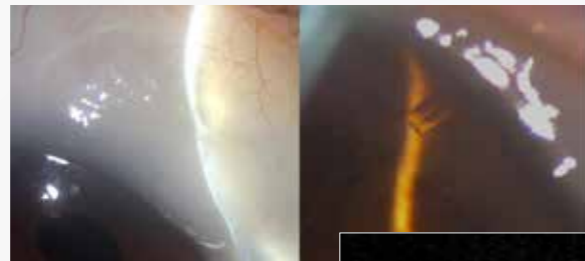Case 3

XEN® Gel Stent* Glaucoma Surgery (Post-op 2 years)

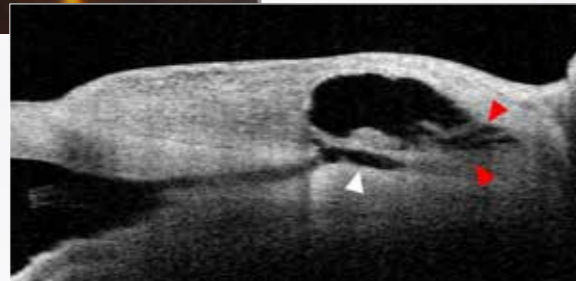
After a subconjunctival bleb-forming surgery, it is important to assess the exact location of the implanted device and its relation to the different ocular structures. Ensuring positioning of the distal end of the XEN® Gel Stent can predict surgical outcomes. Both eyes of the same patient are presented, with different XEN® placements and bleb morphology, but with successful results in both cases.

Right eye (OD) – Sub-Tenon’s XEN® Gel Stent implantation

Although the distal end of the device was not visible by the means of the slit-lamp examination, CASIA2 was able to confirm its sub-Tenon’s placement (white arrow head) and the presence of filtration at that level (red arrow heads).




Anterior segment images



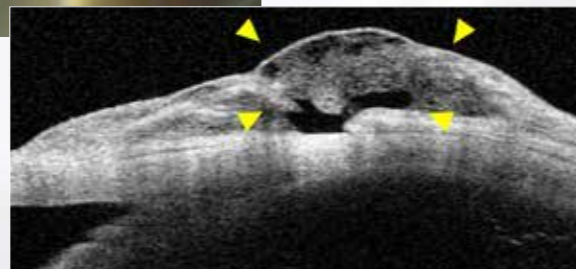
CASIA2 cross-sectional image using "bleb" mode

Left eye (OS) – Subconjunctival XEN® Gel Stent implantation

Positioning the distal end of the device (red arrow head) beneath the conjunctiva led to subconjunctival filtration (yellow arrow heads), and a hyporefective bleb with microcysts. All of these features can be evaluated with CASIA2.

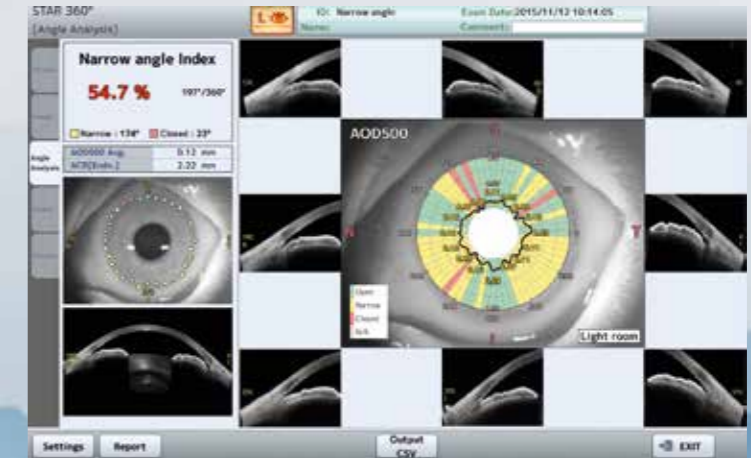

Anterior segment images



*AbbVie Inc., Chicago, Illinois, USA

CASIA2 cross-sectional image using "bleb" mode



Glaucoma application

With our STAR 360° application, the CASIA2 automatically measures the anterior chamber angles all around the anterior segment – thanks to its automatic scleral spur detection. It provides you with specific parameters needed to detect and treat glaucoma. With the added function "Narrow Angle Index"* you immediately receive data about a possible narrow angle plus a referring index based on normative data.

*available from version 60, optional feature "STAR Analysis software"



Dr. Pau Romera
Hospital Universitari Germans Trias i Pujol,
Barcelona (Spain)

Case 1

Post-DSAEK Complications and Cataract Surgery in Fuchs' Dystrophy

This concerns a patient with bilateral Fuchs' dystrophy whose history includes DSAEK surgery in the right eye with subsequent ocular hypertension due to misdirection syndrome, requiring pars plana Vitrectomy and Goniosynechialysis in the same procedure. The patient presented significant photophobia and cataract, with intraocular pressure of 18 mmHg (figure 1).

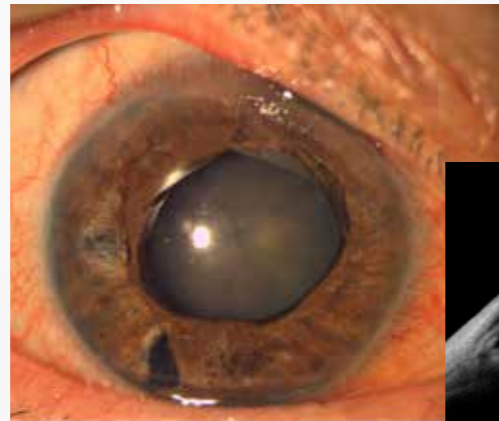


Figure 1

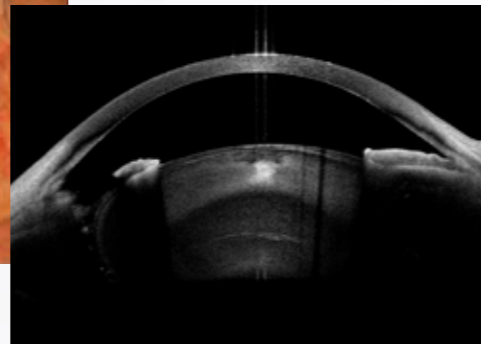


Figure 2

CASIA2 images inform us about corneal transparency and good adaptation of the endothelial graft, but also allows us to visualise the integrity of the lens after inferior iridectomy and gives us a 360° visualisation of the iridocorneal angle (figure 2).




Figure 3

In this case, a narrow angle with no presence of previous synechiae in all four quadrants is observed (figure 3). Given this situation, cataract surgery will be proposed with pupillary sphincter reconstruction using iris cerclage, with no associated glaucoma surgery as part of the procedure at this time.

Case 2

Advanced Imaging of Preserflo Microshunt in Uveitic Glaucoma Treatment

This is a 50-year-old male patient who had a history of uveitic glaucoma in his left eye, with previous Non-Penetrating Deep Sclerectomy surgery. It was decided to re-intervene in this eye after presenting pressures of 30 mmHg, performing a Preserflo Microshunt surgery (Santen, Osaka, Japan) in the superior temporal quadrant.

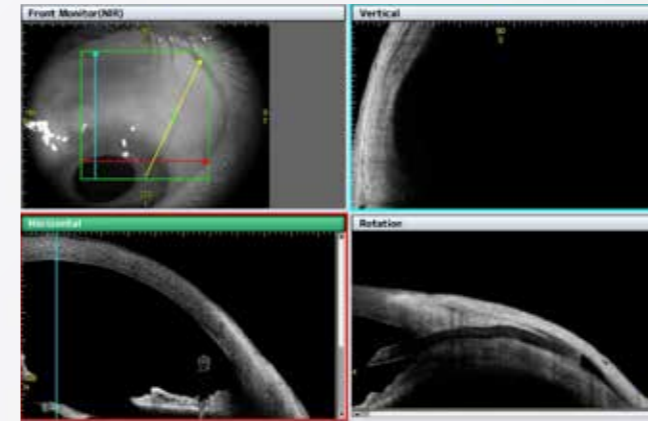


Figure 1

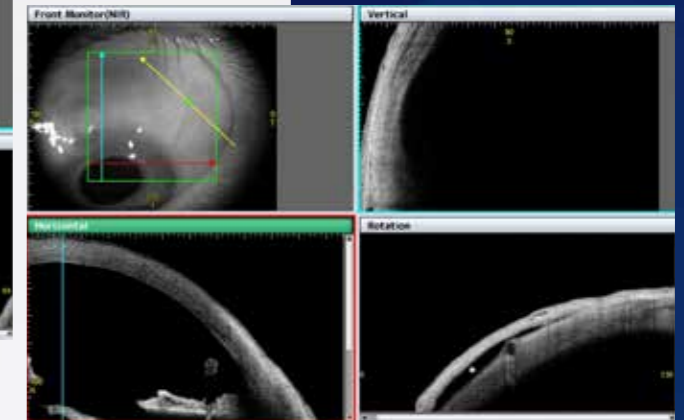


Figure 2

CASIA2 images allow us to locate the intraocular portion of the implant, calculate the distance from the tip of the tube to endothelium, as well as visualise the entire tube pathway, its internal lumen (figure 1), and the presence of posterior conjunctival bleb, visualised as a hyporeflexive area in the most posterior part of the implant (asterisk in figure 2).

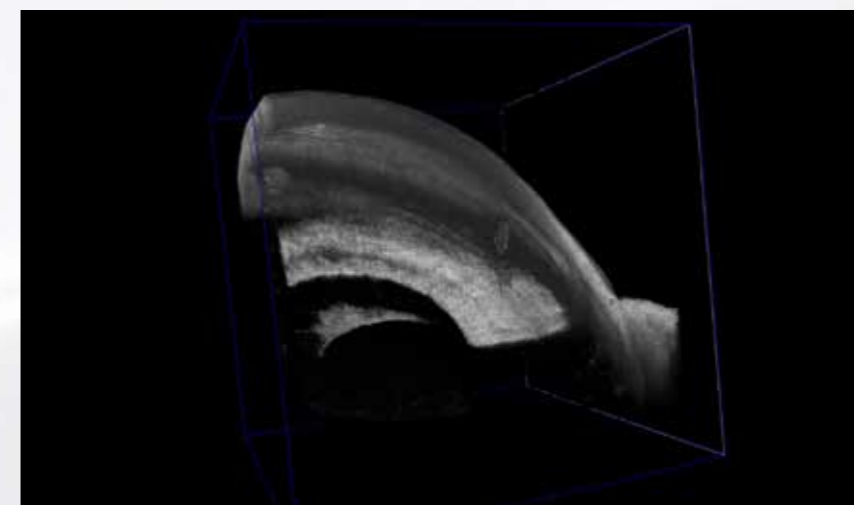


Figure 3

We can also make a 3D reconstruction of anterior segment localising the tube entrance (figure 3). The current pressure is 10 mmHg.

Case 3

Long-term Success of Esnoper Clip Sclerectomy in Chronic Glaucoma

This is an 80-year-old woman with chronic open-angle glaucoma with poor pressure control despite maximum pharmacological treatment. On examination, pressures of 22 mmHg are found in both eyes with terminal glaucomatous optic nerve damage. It was decided to perform Non-Penetrating Deep Sclerectomy with Esnoper Clip implant (AJL, Alava, Spain) in both eyes. After one year, diffuse well-vascularised blebs are present in both eyes (figure 1: right eye; figure 2: left eye).

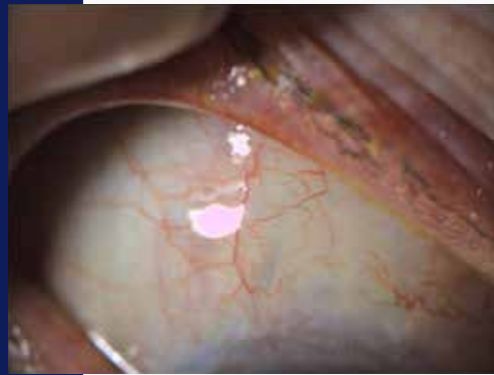

Figure 1

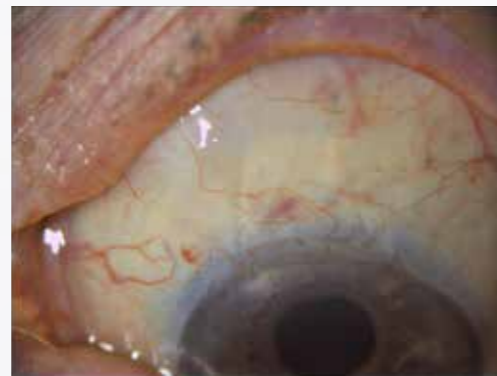

Figure 2

CASIA2 allows us to obtain images of the conjunctival bleb, visualising the presence of subconjunctival cystic spaces, the integrity of the intra-scleral lake, and posterior transscleral flow (figure 3, right eye, arrow), as well as visualising the presence of supraciliary filtration allowed by this implant.



Figure 3

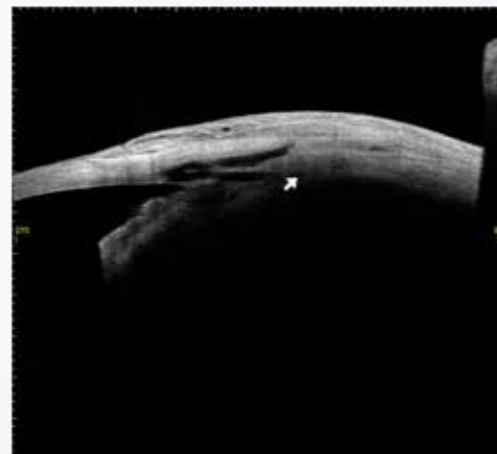
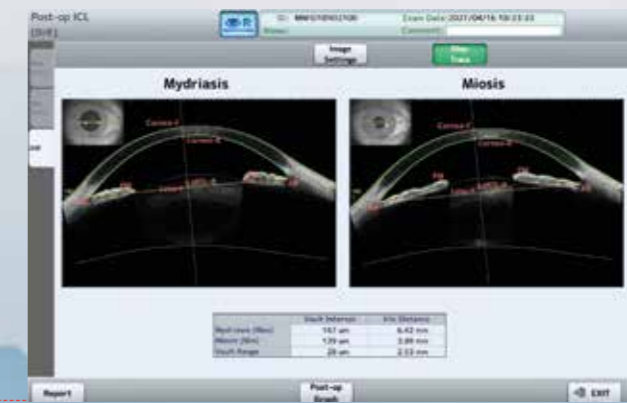
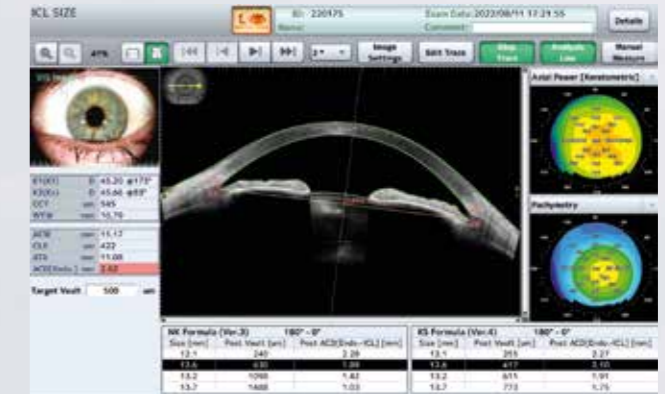
Figure 4

In the left eye section, supraciliary flow can be visualised (figure 4, left eye, arrow). Pressures after one year were 8 mmHg in the right eye and 5 mmHg in the left eye.



ICL surgery

Pre-OP ICL: With two different integrated size recommendation formulas, this application enables the doctor to confirm the correct sizing for ICL surgery.

Post-OP ICL: The Post-OP ICL movie function* controls the dynamic vault and shows the vault under mydriasis and miosis conditions as well as the relevant vault range difference. A fantastic tool for a proper quality check.

*available from version 60; Reference study: "Dynamic Assessment of Light-Induced Vaulting Changes of Implantable Collamer Lens with Central Port by Swept-Source OCT: Pilot Study" Dr. Felix Gonzalez-Lopez; Madrid, Spain.



Dr. Stephan Szegedi

Department of Ophthalmology,
Clinic Hietzing, Vienna Healthcare Group,
Vienna (Austria), Karl Landsteiner Institute
for Process Optimisation and Quality
Management in Cataract Surgery,
Vienna (Austria)

Case 1

Iatrogenic Injury of the Lens Capsule

An 80-year-old woman presented with worsening vision five days after an intravitreal anti-vascular endothelial growth factor injection for age-related macular neovascularisation. The patient's file noted early dementia and reduced cooperation during intravitreal injections. Best-corrected visual acuity (BCVA) had declined from 0.5 pre-injection to 0.05 at presentation. Slit-lamp examination revealed a clear cornea, quiet anterior chamber, nuclear cataract, and probable defect of the posterior lens capsule (Figures 1 and 2). The fundus view was limited, but no signs of endophthalmitis were recorded.




Figure 1

Figure 2

Anterior segment OCT demonstrated a posterior lens capsule injury (Figure 3), suspected to be iatrogenic from the recent intravitreal injection. This diagnosis guided the decision to perform lens extraction under general anesthesia with vitrectomy standby.

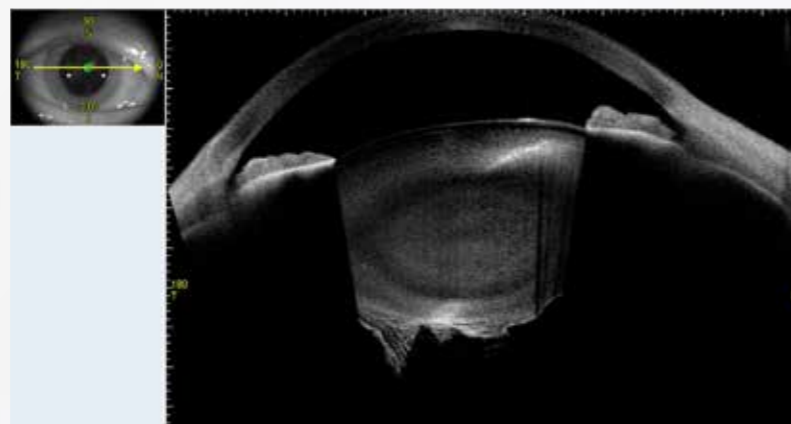


Figure 3

Intraoperatively, the capsular defect led to nucleus drop into the vitreous cavity, necessitating vitrectomy and sulcus intraocular lens implantation. Postoperatively, BCVA improved to 0.63 after nine days.

This case highlights the utility of high-resolution anterior segment OCT in definitively diagnosing posterior capsule injuries. The imaging modality provided objective preoperative information, allowing for appropriate surgical planning in managing this uncommon complication of intravitreal injections.

Case 2

Pupillary Block Caused by Phakic Intraocular Lens

A 53-year-old man was referred for evaluation following a five-day history of intermittent pressure sensation and vision loss in the left eye. The referring ophthalmologist had initially recorded an intraocular pressure (IOP) of 35 mmHg OS and initiated treatment with oral acetazolamide. Twenty-two years prior, at age 31, the patient had undergone bilateral implantation of angle-supported phakic intraocular lenses (ACIOLs) with superior iridectomies to address high myopia.

Upon examination, best-corrected visual acuity was 0.4 OD and 0.63 OS. IOP had normalised to 10 mmHg OD and 12 mmHg OS with the acetazolamide treatment. Slit-lamp examination revealed a shallow anterior chamber (AC) in the left eye with iris bombé configuration. The iris also showed signs of pigment dispersion. The superior iridectomies performed during the original ACIOL implantation were not visible.

Anterior segment OCT demonstrated angle closure in approximately one-third of the circumference in the left eye, confirming iris bombé in the inferonasal and superotemporal quadrants (Figure 1). The right eye showed an open-angle configuration (Figure 2). The OCT also visualised the ACIOL position and its relationship to the iris. Gonioscopy confirmed these findings.

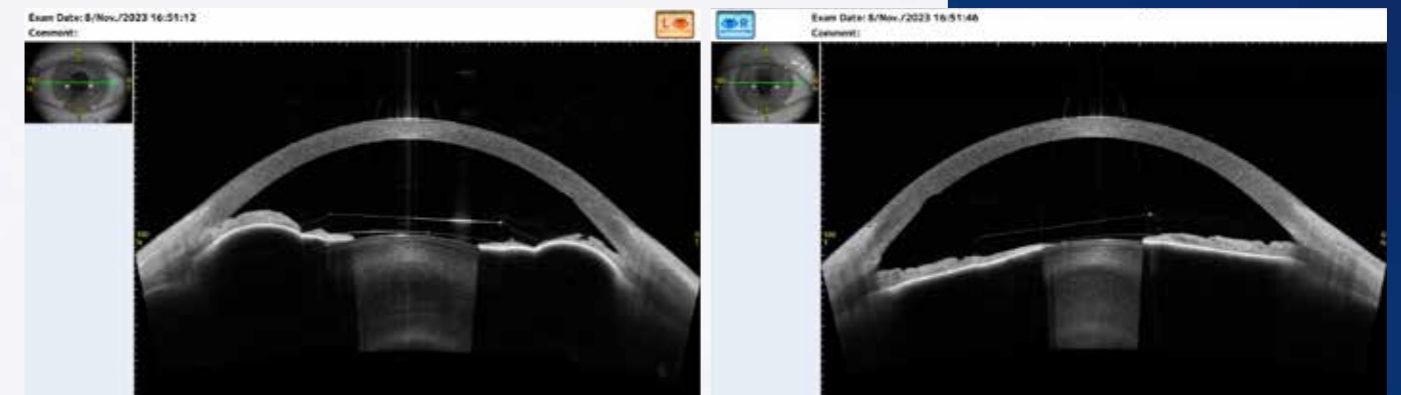


Figure 1

Figure 2

A fundus examination and optic nerve head OCT revealed borderline glaucomatous changes in both eyes, more pronounced in the left.

Based on these findings, surgical intervention was planned. The anterior chamber IOL was explanted through a scleral tunnel approach. This was followed by an uneventful phacoemulsification with implantation of a posterior chamber IOL in the capsular bag.

This case highlights the utility of anterior segment OCT in objectively documenting and quantifying the extent of angle closure in late-onset pupillary block following ACIOL implantation, even in the presence of a surgical iridectomy and normalised IOP after initial treatment. OCT imaging was the ideal means for providing documentation and objective information for treatment planning. The case also underscores the importance of long-term follow-up in patients with ACIOLs.

Case 3

Management of Capsular Bag Phimosis

A 63-year-old woman was referred for laser capsulotomy for capsular phimosis diagnosed three months after uneventful bilateral cataract surgery. During examination, pinhole capsular phimosis was noted.

Anterior segment OCT imaging was employed to document and visualise the extent and unusual thickness of the phimotic capsular bag.

Nd:YAG laser capsulotomy was performed over three sessions, with 150-600 mJ of laser energy applied per eye per session. OCT was utilised to monitor the progress of the interrupted surgical treatment, allowing for documentation of the capsulotomy's extent and effectiveness (Figure 1: after first capsulotomy, Figure 2: follow-up visit after final treatment).

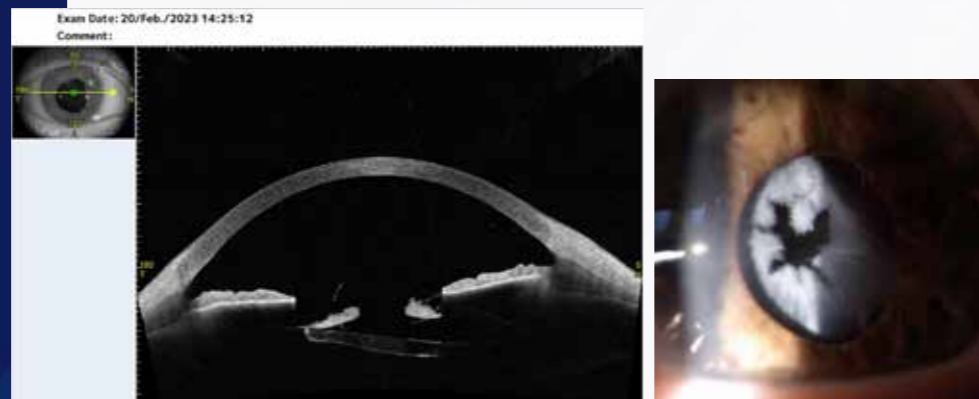


Figure 1

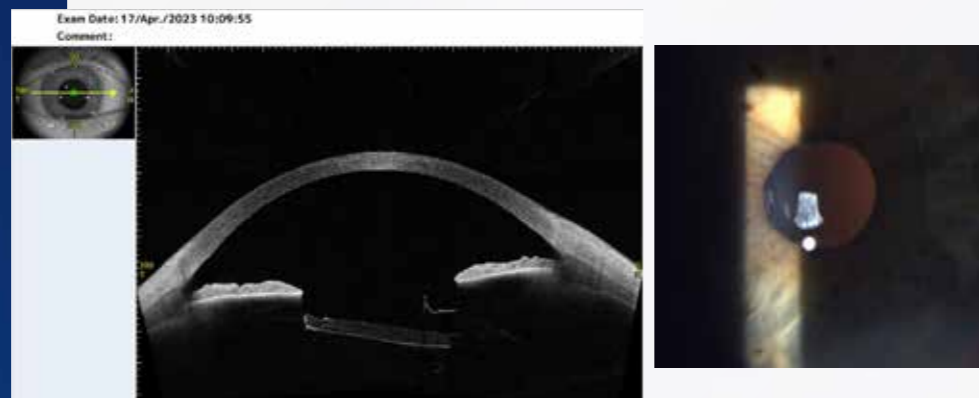


Figure 2

For postoperative treatment, NSAID and cortisone eye drops were prescribed. Despite this, the patient developed mild cystoid macular edema postoperatively. With continued treatment, macular edema resolved over a one-month period.

OCT was utilised to document the extent and unusual thickness of the phimotic capsular bag and allowed for assessment of the progress during the multi-session treatment.

Join this project

Do you also have interesting cases that could be valuable for other ophthalmologists?

Then feel free to contribute to this brochure.

Please contact us at marketing@tomey.de – we really look forward to hearing about your practical experiences with our AS-OCT CASIA2.

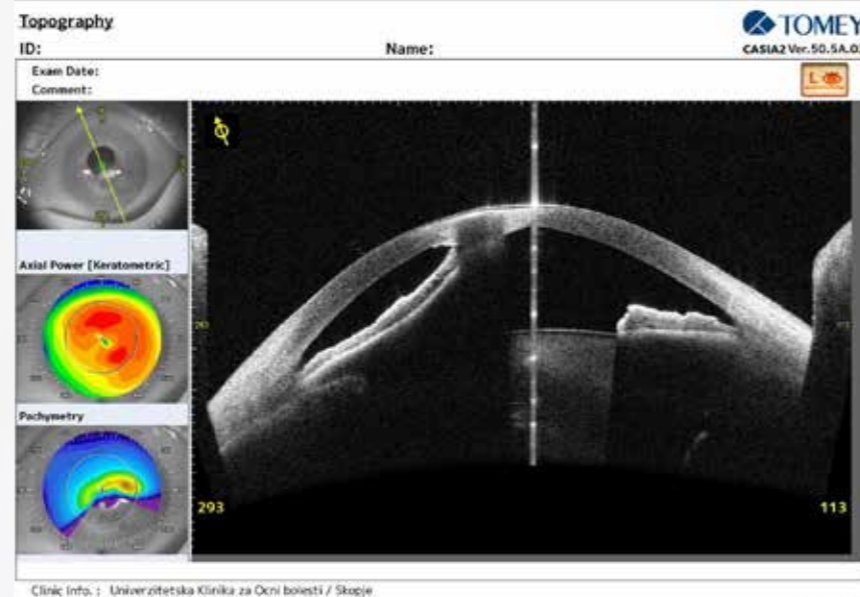
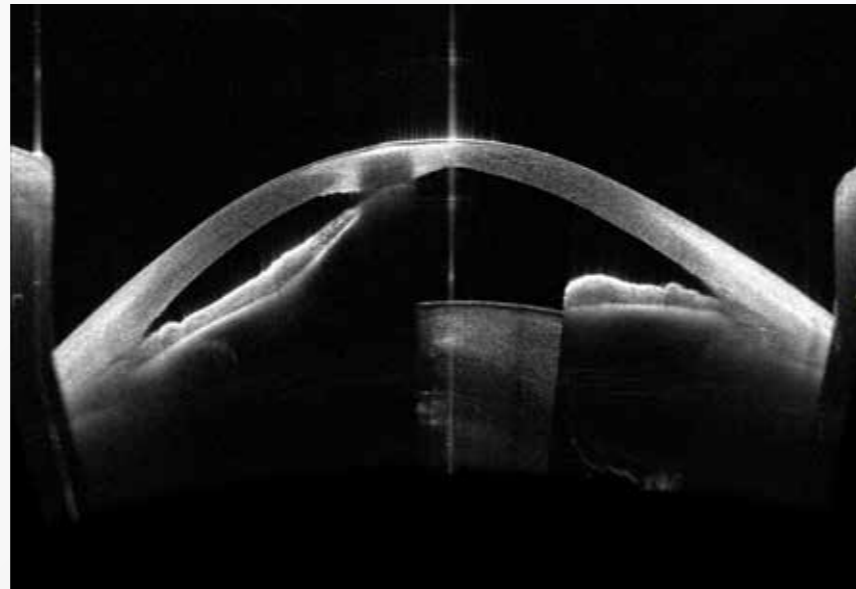


Ana Trpeska Boshkoska MD
Ophthalmologist, PHI University Clinic
for Eye Diseases, Skopje (N. Macedonia),
Teaching assistant

Case 1

Peters Anomaly

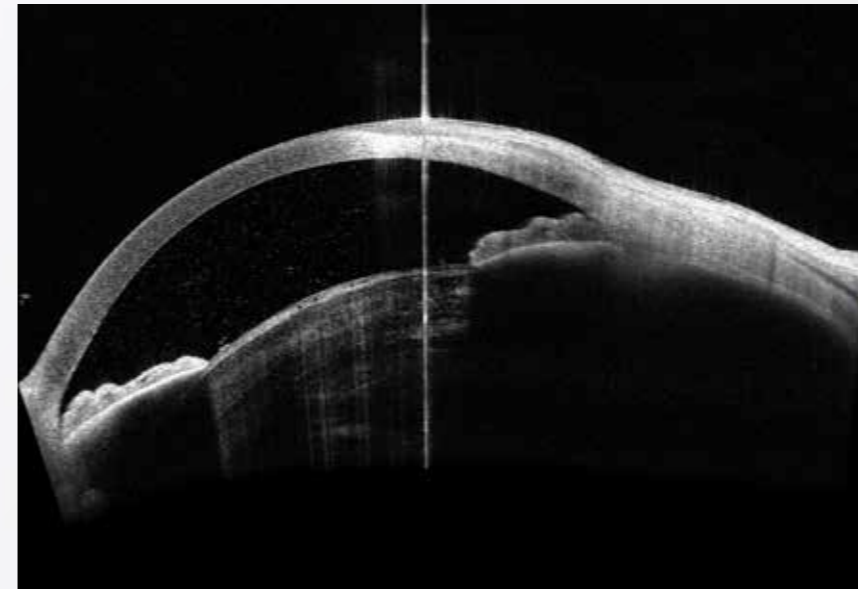
This CASIA2 OCT tomographic image shows a case of a 58-year-old patient with unilateral Peters Anomaly. Corneal opacity and iridocorneal adhesions are present. There are no lenticulocorneal adhesions.



Case 2

Phacolytic Glaucoma

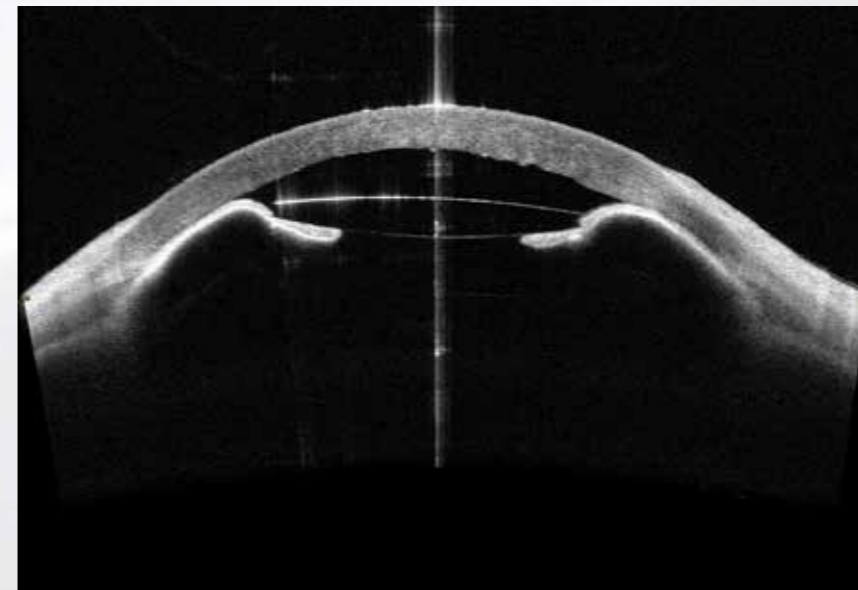
With CASIA2, the presence of lens proteins and protein-containing macrophages in the anterior chamber is easily noticeable, as in this case of a patient with a phacolytic glaucoma. Hypermature cataract is visible. Corneal edema is not yet established. There is also advanced pterygium verum present.



Case 3

AC-IOL and Peripheral Iridectomy Not Functioning

This is a case of a patient that underwent cataract surgery and AS-IOL was implanted. The peripheral iridectomy is not functioning, iris bombe is present, intraocular pressure is raised and the AS-IOL is pushed anteriorly. Corneal edema is established.



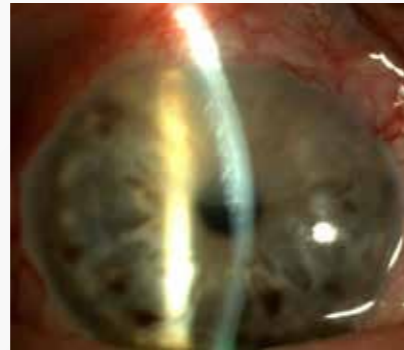


Dr. Jorge Vila Arteaga
La Fe Hospital, Valencia (Spain)

Case 1

Descemet's Detachment – Rare Post-NPGS Complication

A 65-year-old patient underwent deep sclerectomy – non-penetrating glaucoma surgery (NPGS) – for glaucoma five years ago. The IOP was maintained at levels between 11-13 mmHg during this time. He went to the emergency room due to decreased visual acuity in the operated eye. IOP was 12 mmHg.



Corneal edema was observed and treatment was started with topical corticosteroids and hyperosmolar agents. He was referred to the Glaucoma Unit.

On examination we found a superior, semicircular, and well-differentiated corneal edema (Figure 1). For the correct diagnosis, AS-OCT is performed using CASIA2.

Figure 1

In the surgical area, the scleral lake (SL) and the trabeculo-Descemet window (TDW) can be seen. There is corneal thickening and detachment of Descemet's membrane (***) (Figure 2).

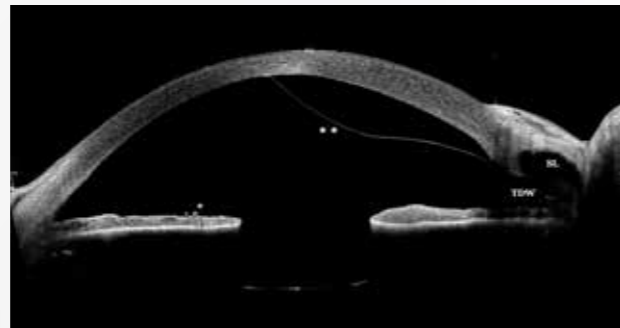


Figure 2

Descemet's membrane detachment is an unusual complication of NPGS that is often associated with an increase in IOP due to a tenon cyst. On this occasion the IOP was within normal limits. Its diagnosis is very complex if AS-OCT is not available, because with the slit lamp it is not possible to differentiate the Descemet's membrane due to the clouding of the cornea. The treatment consists of injection of 20% SF6 in the anterior chamber (Figure 3) which manages to apply the membrane. This is constable using the AS-OCT (Figure 4).

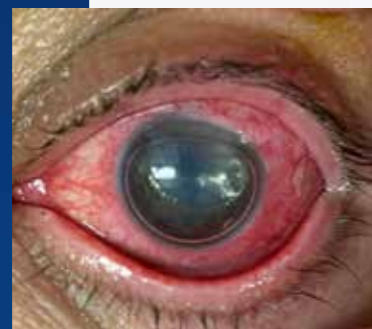

Figure 3

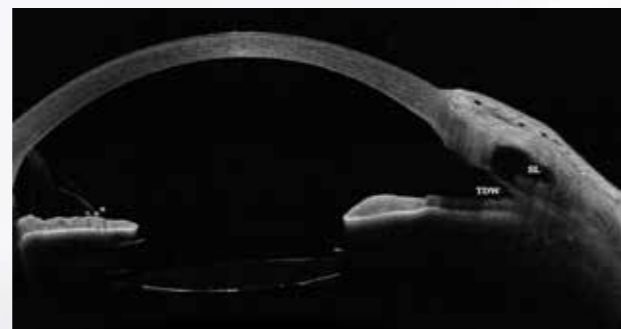

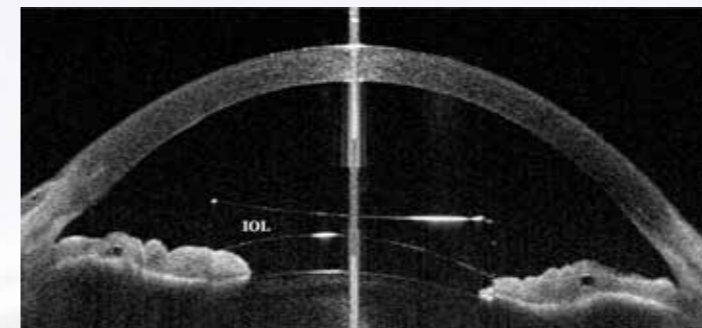
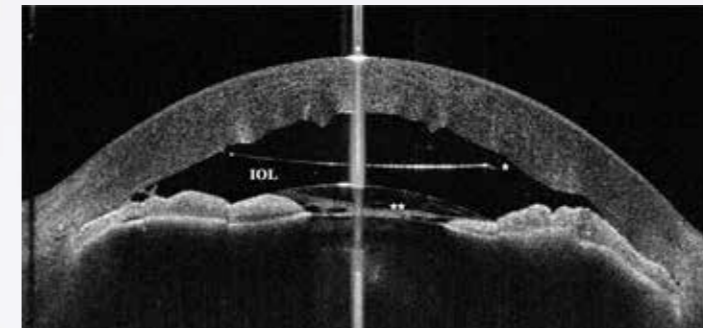
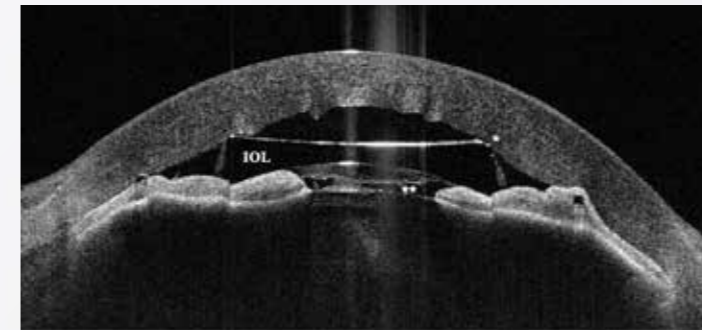
Figure 4

Case 2

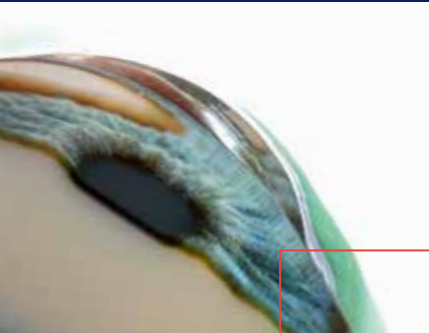
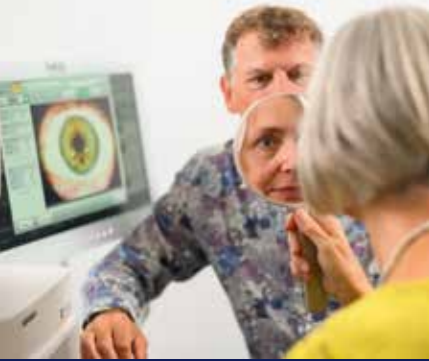
Post-Surgery Corneal Edema and Athalamia in Glaucoma

A 45-year-old woman underwent phakic anterior chamber lens surgery 23 years ago. She develops glaucoma and undergoes a trabeculectomy. The day after surgery the chamber is wide, the IOP is 5 mmHg.

At the weekly check-up, the patient presented with corneal edema and athalamia. She underwent intensive treatment with mydriatic agents and corticosteroids. Performing an AS-OCT using CASIA2 allows all parameters to be monitored qualitatively and quantitatively: corneal edema, distance from the lens to the endothelium(*), irido-corneal contact, and the inflammatory pupillary membrane(**).



After 30 minutes the improvement was already visible on the OCT, and the next day the improvement could be quantified. In 3 days the clinical condition was resolved.



Special CASIA2 use case: apEye, the artificial prosthetic eye

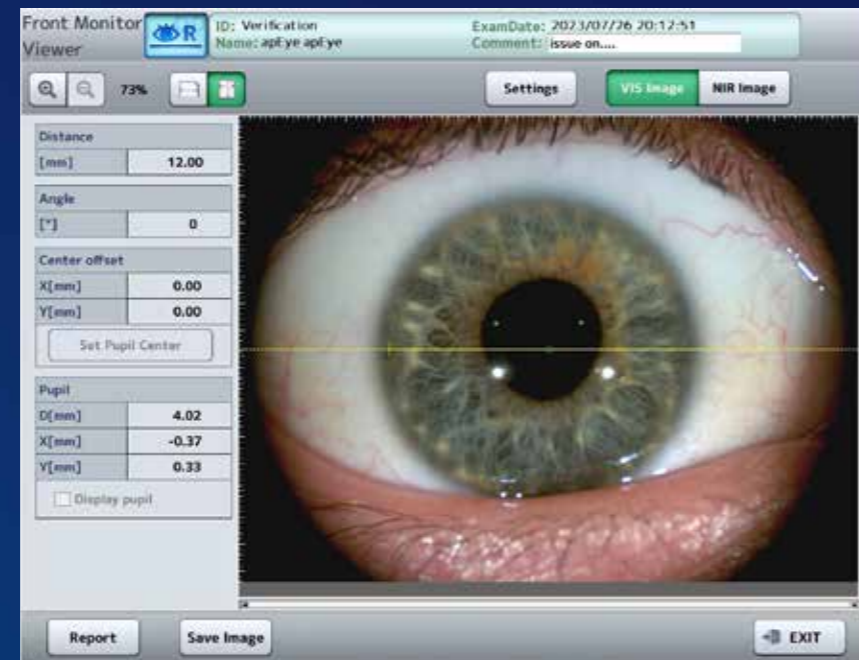
What is apEye?

apEye opens up a whole new range of possibilities in diagnostics and the 3D manufacture of ocular prosthetics. The digital workflow is simple, efficient, and pain-free for the patient. Our focus is on people, or to be more precise, patients who depend on an “artificial prosthetic eye” – apEye – but also on doctors, ophthalmologists, hospitals and clinics. Everyone benefits from the scientific and technical advances that have been brought together with the 3D-printed ocular prosthetic. It is a technology breakthrough that showcases true colours and unique iris topography.

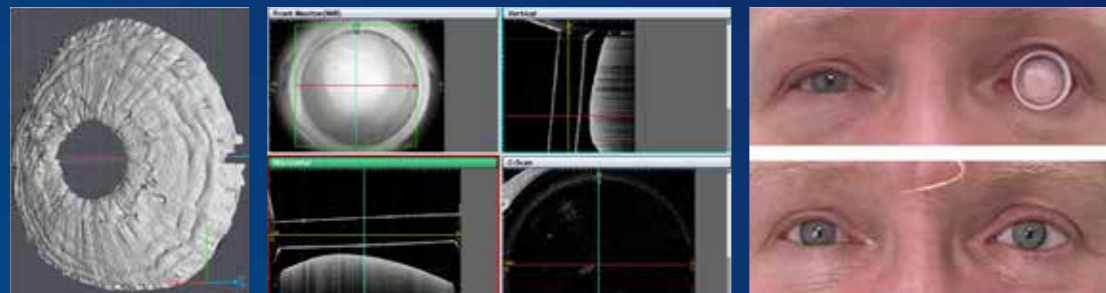
Partners

TOMEY and OCUPYE have brought several strong partners on board for apEye. With software support from the renowned Fraunhofer Institute in Darmstadt, the medical expertise of the highly regarded Moorfields Eye Hospital in London, and the experience in additive manufacturing of FIT Prototyping GmbH, all the key areas of the entire project have been populated with prestigious players – from the first scan to the processing of the data and to the printing, and the medical studies and trials.

More information:
www.apEye.de/en



Fellow eye scan (AS Global scan)



You + eye. We care.

Special thanks
to all the experts
who submitted their
practical cases.

**TOMEY EUROPE
TOMEY GMBH**

Wiesbadener Strasse 21
90427 Nuremberg | Germany
+49 911 938 546 2 - 0
info@tomey.de

[tomey.de](https://www.tomey.de)

Follow TOMEY



TOMEY GmbH is the European headquarters of TOMEY Corporation, 2-11-33 Noritakeshinmachi Nishi-Ku, Nagoya, 451-0051, Japan



The statements of the ophthalmologists who provided testimonials only reflect their personal opinions and experiences and do not necessarily reflect the opinions with whom they are affiliated. The ophthalmologists giving these testimonials may have a contractual relationship with TOMEY GmbH and may have received financial compensation.

Always read and follow the instructions for use.
Not all products, services or offers are approved or offered in every market.
Please note that the current status of approval for the labelling, instructions and contents of the brochure may vary from one country to another.